

# UCLA

## UCLA Previously Published Works

### Title

Comparison of residual shunt rates in five devices used to treat patent foramen ovale

### Permalink

<https://escholarship.org/uc/item/0v5234v5>

### Journal

Catheterization and Cardiovascular Interventions, 84(3)

### ISSN

1522-1946

### Authors

Matsumura, Koichiro

Gevorgyan, Rubine

Mangels, Daniel

et al.

### Publication Date

2014-09-01

### DOI

10.1002/ccd.25453

### Copyright Information

This work is made available under the terms of a Creative Commons Attribution License, available at <https://creativecommons.org/licenses/by/4.0/>

Peer reviewed

# PEDIATRIC AND CONGENITAL HEART DISEASE

## Original Studies

### Comparison of Residual Shunt Rates in Five Devices Used to Treat Patent Foramen Ovale

Koichiro Matsumura, MD, Rubine Gevorgyan, MD, Daniel Mangels, MS, Reza Masoomi, MD, Mohammad Khalid Mojaddi, MD, and Jonathan Tobis,\* MD FACC

**Objectives:** To assess the effective closure rate among devices used for transcatheter patent foramen ovale (PFO) closure, and to discuss the management of patients with large residual shunts. **Background:** Several devices are used off-label for transcatheter closure of a PFO in the United States. The rate of residual shunting after PFO closure varies by device. Failure of effective closure poses risk of a recurrent cerebrovascular event, persistent migraine, or recurrent orthodeoxia. **Methods:** Patients who underwent PFO closure in the Cardiac Catheterization Laboratory at UCLA between 2001 and 2013 and had baseline and adequate follow-up transcranial Doppler studies following device placement were enrolled in the study. **Results:** Of 167 patients whose records were analyzed, effective PFO closure occurred in 90% (150/167) of patients. The highest effective closure rate was with the Amplatzer Septal Occluder (ASO; 100%), followed by the Amplatzer Cribriform (93%), Gore Helex (90%), Amplatzer PFO (86%), and CardioSEAL (86%) device. The highest rate of residual shunting was observed after placement of the 30-mm Gore Helex device (55%). Of the 17 patients with a residual shunt, three required a repeat PFO closure procedure due to a significant residual shunt associated with recurrent pulmonary emboli or profound orthodeoxia. All three patients received an ASO which successfully closed the residual shunt. **Conclusions:** Transcatheter PFO closure has a high success rate, but a moderate residual shunt occurs in about 10% of cases. The observed incidence of residual shunting after PFO closure is significantly larger with the 30-mm Helex device. © 2014 Wiley Periodicals, Inc.

**Key words:** patent foramen ovale; atrial septal defects; percutaneous closure of PFO

## INTRODUCTION

Patent foramen ovale (PFO) is a remnant of the fossa ovalis from the fetal circulation, persisting in about 25% of the adult population [1]. Right-to-left shunting, commonly through a PFO, is associated with numerous adverse health risks, including cryptogenic stroke, transient ischemic attacks (TIA), migraine with aura, orthodeoxia, and exacerbation of sleep apnea [2–8]. A meta-analysis of observational studies and the combined data from the RESPECT and PC Trials suggest that PFO occluding devices reduce the recurrence of stroke and TIA at higher rates than conventional medical treatment alone [9–11]. Despite the absence of specific Food and Drug Administration labeling, it is not uncommon for PFO closure to be requested by physicians for patients with one of these

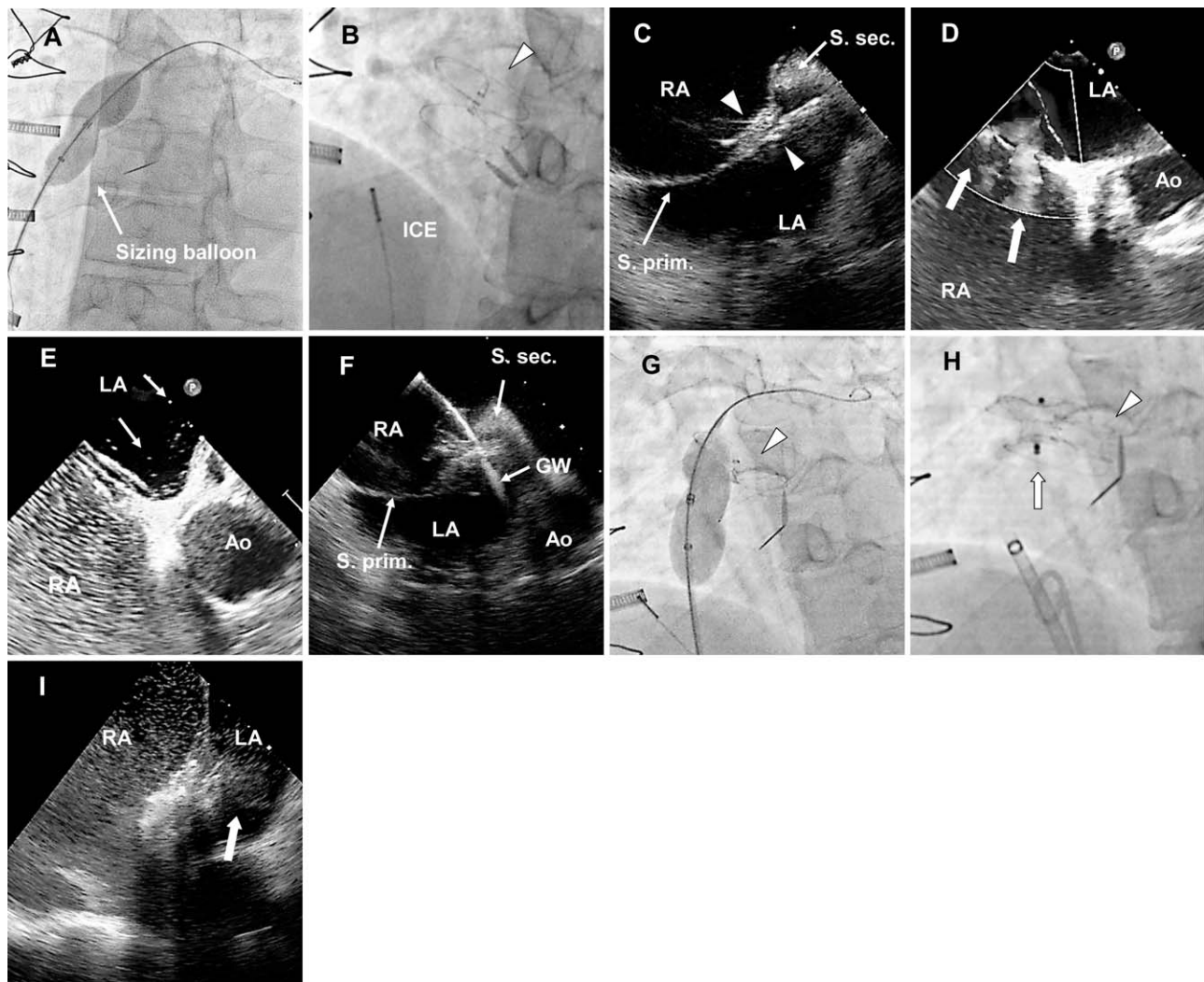
Program in Interventional Cardiology, Division of Cardiology, David Geffen School of Medicine, University of California at Los Angeles, Los Angeles, California

Conflict of interest: Dr Tobis was a consultant for AGA Medical, Inc.; W.L.Gore, Inc.; and Coherex, Inc. AGA Medical Inc provided the transcranial Doppler system and an unrestricted grant to support this research.

\*Correspondence to: Jonathan Tobis; Director of Interventional Cardiology Research, UCLA, B976 Factor Building CHS, 10833 Le Conte Avenue, Los Angeles, CA 90095. E-mail: Jtobis@mednet.ucla.edu

Received 4 September 2013; Revision accepted 16 February 2014

DOI: 10.1002/ccd.25453  
Published online 19 February 2014 in Wiley Online Library (wileyonlinelibrary.com)



**Fig. 1.** Case 1: (A) A sizing balloon measurement demonstrates that the PFO size is 15 mm. (B) The 30-mm Helex device (arrowhead) is deployed. ICE, intracardiac echocardiography. (C) ICE shows the Helex device (arrowheads) is deployed in the correct position. S. sec, septum secundum; S. prim, septum primum; LA, left atrium; RA, right atrium. (D) Right-to-left shunting (arrows, blue jet on color Doppler) is demonstrated on TEE. LA, left atrium; RA, right atrium; Ao, aorta. (E) Micro bubbles (arrows) are demonstrated moving across the Helex device (TEE). (F) ICE demon-

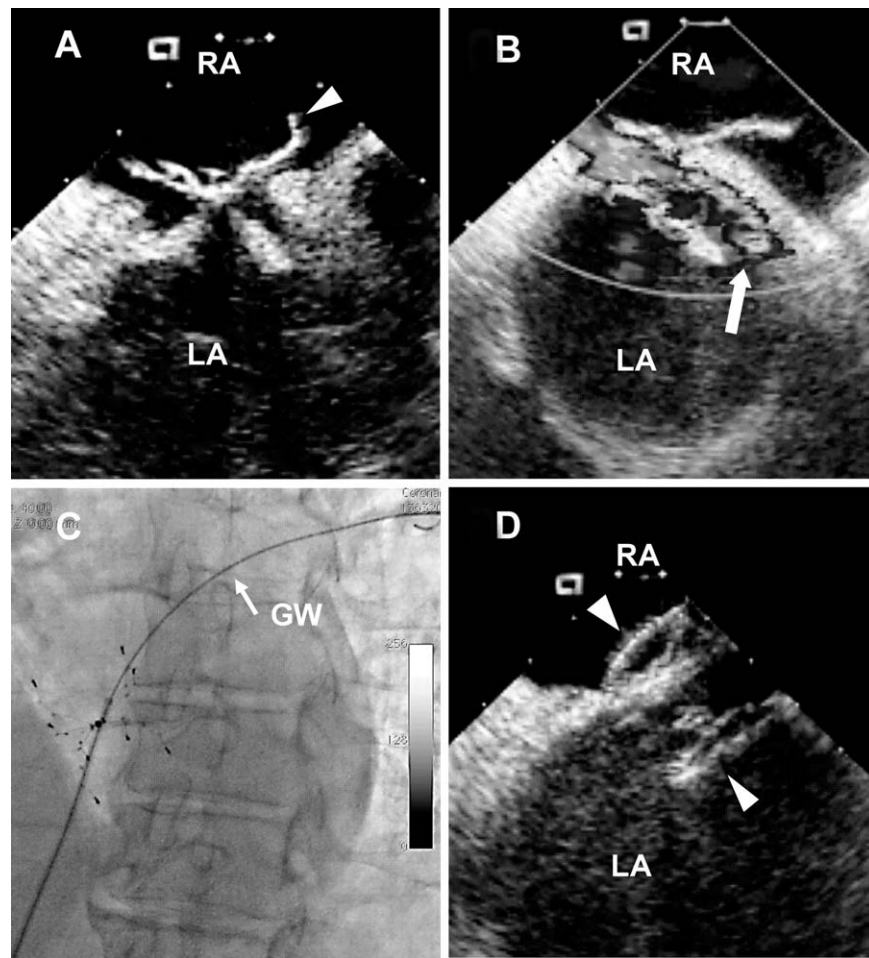
strates a guide wire passed across the Helex device into the left atrium. LA, left atrium; RA, right atrium; Ao, aorta; GW, guide wire; S. sec, septum secundum; S. prim, septum primum. (G) A sizing balloon is placed through the residual PFO defect along side of the original Helex device (arrowhead). (H) The Helex device (arrowhead) and additional Amplatzer ASD Occluder (arrow). (I) After deployment of the additional device, a bubble study shows decreased flow across the septum (arrow).

PFO-associated conditions. In the past decade, several devices have been used for transcatheter PFO closure. Although selection of the appropriate device is essential to effectively close the PFO, the closure rates of different devices have not been well described. In this retrospective study, the degree of right-to-left shunting was quantified following placement of five different PFO closure devices: the Amplatzer Septal Occluder (ASO), the Amplatzer “Cribriform” Septal Occluder, the Amplatzer PFO Occluder, the CardioSEAL Septal Occluder, and the Gore Helex Septal Occluder. Three

cases are described involving repeat transcatheter PFO closure due to significant residual shunting (Figs. 1–3).

## MATERIALS AND METHODS

From January 2001 to January 2013, 327 patients confirmed to have right-to-left shunting through a PFO underwent transcatheter closure of their PFO using one of five occluding devices: (1) ASO, (2) Amplatzer “Cribriform” Septal Occluder, (3) Amplatzer PFO



**Fig. 2. Case 2: (A)** The arms of the CardioSEAL device (arrowhead) protrude into the right atrium (ICE). LA, left atrium; RA, right atrium. **(B)** Left-to-right shunting at rest (arrow, blue jet on color flow) is present through the original device by color Doppler echocardiography. **(C)** A standard J-wire is passed through the residual PFO shunt. GW, guidewire. **(D)** An additional 25-mm Amplatzer Cribriform occluder device (arrowheads) is deployed.

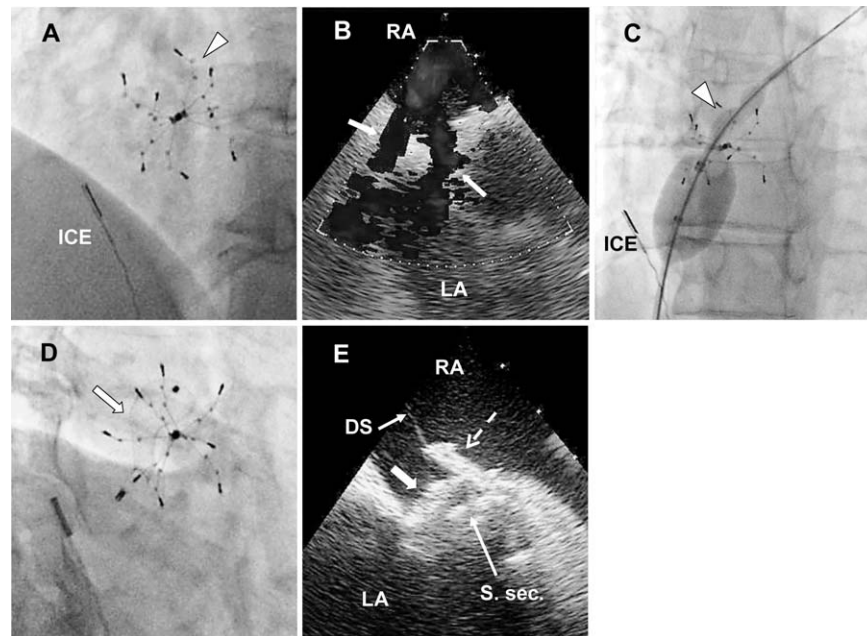
Occluder, (4) CardioSEAL Septal Occluder, and (5) Gore Helex Septal Occluder.

Transcranial Doppler (TCD) is a noninvasive alternative means of detecting right-to-left shunting with a sensitivity higher than transesophageal echocardiogram (TEE) (98% with TCD and 91% with TEE) when catheterization is used as the reference [12].

In 204 patients, the presence and severity of right-to-left shunting was assessed prior to PFO closure using contrast TCD with agitated saline. The study was conducted using a Power M-mode TCD (Terumo 150 PMD). A headband with bilateral temporal ultrasound probes was placed on the patient's head. Bilateral middle cerebral artery signals were obtained via temporal acoustic windows. After establishing an intravenous access in a brachial vein, a mixture of 8 ml of saline, 0.5 ml of air, and 1 ml of blood was agitated between two 10-ml syringes connected via a three-way stopcock

and then injected. The injection was performed at rest and with the Valsalva maneuver. To facilitate an effective straining effort with the Valsalva maneuver, the patients were asked to forcefully exhale into a tube connected to a manometer and maintain the manometer gauge at 40 mmHg for 10 sec. The TCD screen was monitored for 1 min following the injection of agitated saline. TCD results were categorized from grade 0 to grade 5 using the Spencer Logarithmic Scale (Table I). Visualization of greater than 30 microbubbles was considered a positive shunt which correlated to grade 3 or higher on the Spencer scale. Following the device placement, follow-up TCD studies were performed to evaluate for residual shunting. TCD was performed after 3 months and repeated every 3 months until complete closure or up to 12 months, whichever came first. If patients were unavailable for follow-up studies, TCD measurements were performed at the most convenient





**Fig. 3.** Case 3: (A) The CardioSEAL device (arrowhead) is visualized by fluoroscopy. ICE-intracardiac echocardiography probe. (B) Baseline left-to-right shunting (arrows, a blue jet on color flow Doppler) is demonstrated with ICE. LA, left atrium; RA, right atrium. (C) A sizing balloon shows that the residual PFO tunnel size is approximately 15-mm long and 6-mm wide (arrowhead). (D) Ten millimeter Amplatzer device (arrow) is

deployed within the residual PFO tunnel. (E) The right atrial disk of the Amplatzer device (solid arrow) is deployed between the CardioSEAL spider arm (dotted arrow) and Septum secundum. The delivery system (DS) is connected to the right atrial disk of the Amplatzer device. S. sec, septum secundum.

**TABLE I.** Spencer Logarithmic Scale for TCD Grading

| Grade   | Microbubbles (mB) |
|---------|-------------------|
| Grade 0 | 0                 |
| Grade 1 | 1–10              |
| Grade 2 | 11–30             |
| Grade 3 | 31–100            |
| Grade 4 | 101–300           |
| Grade 5 | >300              |

time for the patient. An effective closure was defined as a Spencer grade of 0, 1, or 2, while residual shunting was defined as a Spencer grade of 3 or higher during either rest or Valsalva maneuver. Residual shunting was defined as the presence of Spencer grade of 3 and above on TCD  $12 \pm 2$  months after device placement.

Statistical significance was determined using the Chi square test; a value of  $P \leq 0.05$  was considered significant. Closure rate was plotted against time for cases with the Helex device of various sizes using Kaplan–Meier curves.

## RESULTS

Of the 327 patients who underwent PFO closure, 123 had no TCD performed at baseline as they were performed prior to March 2007 when the TCD

**TABLE II.** Demographics of the Study Population

| Variable                           | N (%) or Mean $\pm$ SD |
|------------------------------------|------------------------|
| Total patients                     | 167 (100)              |
| Male gender                        | 72 (43)                |
| Age at consult                     | 51.5 $\pm$ 13.9        |
| Hyperlipidemia                     | 44 (26.3)              |
| Hypertension                       | 32 (19.2)              |
| Diabetes                           | 8 (4.8)                |
| Smoking                            | 12 (7.2)               |
| Diagnosis at referral              |                        |
| Cryptogenic stroke                 | 107 (64.1)             |
| Migraine headache                  | 89 (53.3)              |
| Chronic daily headache             | 5 (3.0)                |
| Migraine aura without headache     | 14 (8.4)               |
| Transient Neurological symptoms    | 27 (16.2)              |
| Myocardial Infarction              | 6 (3.6)                |
| Orthodeoxia                        | 3 (1.8)                |
| Decompression illness              | 3 (1.8)                |
| High altitude sickness             | 8 (4.8)                |
| Sleep apnea                        | 10 (6.0)               |
| Embolic event other than MI or CVA | 2 (1.2)                |
| Use of hormone replacement therapy | 9 (5.4)                |

machine became available. The evaluation of right-to-left shunt in the earlier patients was performed using TEE. Twenty one patients had a baseline TCD but no further follow-up data was available on shunting status; 16 patients have not completed their 1 year follow-up.

**TABLE III. Baseline Characteristics by PFO Devices**

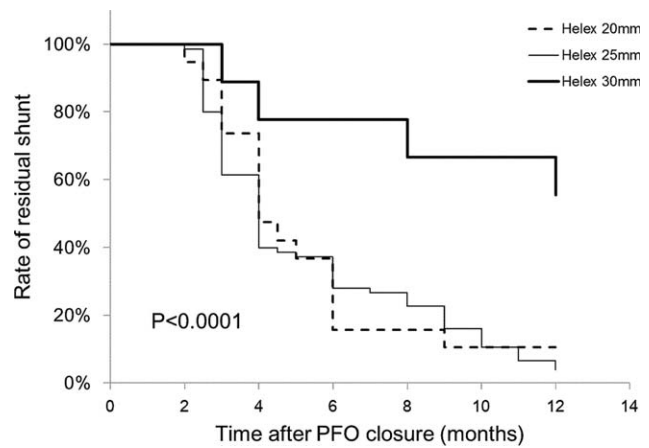
| Device              | Total patients | Male gender, N (%) | Age at procedure, Mean ± SD | Effective closure rate (%) | Effective closure time by TCD | TCD grade on Valsalva at baseline | TCD grade on Valsalva on follow-up (excluding those with residual shunting) |
|---------------------|----------------|--------------------|-----------------------------|----------------------------|-------------------------------|-----------------------------------|---|
| CardioSEAL          | 14             | 6 (43%)            | 49.8 ± 12.7                 | 12/14 (86%)                | 74.1 <sup>a</sup> ± 22.3      | N/A                               | 0.8 ± 0.7   |
| Amplatzer ASO       | 8              | 3 (37%)            | 53.4 ± 12.5                 | 8/8 (100%)                 | 5.1 ± 3.7                     | 3.7 ± 1.7                         | 0.4 ± 0.5   |
| Amplatzer PFO       | 28             | 8 (29%)            | 48.9 ± 11.3                 | 24/28 (86%)                | 42.5 <sup>a</sup> ± 26.6      | 4.6 ± 0.5                         | 0.4 ± 0.7   |
| Amplatzer Cribiform | 14             | 8 (57%)            | 54.5 ± 12.4                 | 13/14 (93%)                | 13.2 <sup>a</sup> ± 5.9       | 4.3 ± 1.1                         | 0.5 ± 0.8   |
| Gore Helex          | 103            | 50 (48%)           | 52.2 ± 15.0                 | 93/103 (90%)               | 5.4 ± 3.4                     | 4.0 ± 1.1                         | 0.6 ± 0.7   |

<sup>a</sup>The majority of these patients had their first follow-up TCD done outside the 12-month window.

**TABLE IV. Gore Helex Device Performance by Size**

| Device size (diameter)                   | 20 (mm)      | 25 (mm)     | 30 (mm)     |
|--|--------------|-------------|-------------|
| Number of patients                       | 19           | 75          | 9           |
| Age at the time of the procedure (years) | 49.0 ± 16.9  | 53.3 ± 15.1 | 49.9 ± 9.7  |
| Presence of atrial septal aneurysm       | 1            | 6           | 1           |
| Spencer grade on Valsalva (pre-closure)  | 4.4 ± 1.0    | 4.0 ± 1.1   | 3.6 ± 1.6   |
| Effective closure month                  | 4.8 ± 2.3    | 5.2 ± 2.8   | 10.7 ± 9.7  |
| Residual shunting rate                   | 2/19 (10.5%) | 3/75 (4%)   | 5/9 (55.5%) |

Table II presents the general demographics of the 167 remaining patients whose data was used in the study analysis. The mean Spencer grade for all devices prior to PFO closure was 3.0 ± 1.6 at rest and 4.2 ± 1.1 during Valsalva. Of the 167 study patients, 8 (5%) received Amplatzer ASO devices (10–20 mm, mode 15), 14 (8%) received Amplatzer Cribiform (25–35 mm, modes 25 and 35), 28 (17%) received Amplatzer PFO (20–30 mm, mode 25), 14 (8%) received CardioSEAL (18–38 mm, mode 28), and 103 (62%) received a Gore Helex device (20–30 mm, mode 25). Following PFO closure, the mean Spencer grade for all PFO-occluding devices at the first follow-up was 0.6 ± 1.1 at rest and 1.3 ± 1.5 during Valsalva. Including patients with late follow-up, the TCD was performed a mean of 17.5 ± 24.8 months after the procedure. The late follow-ups are explained by patients who received their device early in our experience before the TCD was available. These patients were invited back for a follow-up TCD study. Of 167 patients who had their PFOs closed and had available baseline and follow-up TCD studies, effective closure occurred in 150 (90%) patients. Comparison of Spencer grades by device type revealed the highest effective closure rate was associated with the Amplatzer ASO device (100%), followed by the Amplatzer Cribiform (93%), Gore Helex (90%), Amplatzer PFO (86%), and CardioSEAL (86%) device. Effective closure occurred by month 5.1 ± 3.7 using the Amplatzer ASO device, 5.4 ± 3.4 months using the Gore Helex, and 13.2 ± 5.9 months using the



**Fig. 4. Residual shunting rate after 12 months PFO closure, Gore Helex device group, by device size.**

Amplatzer Cribiform (Table III). Those patients with residual shunting had an average TCD grade of 3.9 ± 0.8 on Valsalva at the time of the final TCD follow-up.

At the end of the 12-month follow-up, the highest rate of residual shunting was observed in patients who received the 30-mm Gore Helex device (55.5% residual shunt with the 30-mm Gore Helex compared to 4% with the 25-mm Helex and 10.5% with the 20-mm Helex device; Table IV). When analyzing the cessation of shunting with respect to the time elapsed after device placement, PFO closure progressed rapidly, peaking between months 3 and 6 for patients with the Helex 20 and 25 mm devices; for patients who received the Helex 30 mm device, resolution of PFO shunting took place more slowly ( $P < 0.0001$ ; Fig. 4).

Five patients required placement of an additional device due to significant residual shunting. One received an additional CardioSEAL device at the time of the index procedure due to the presence of a fenestrated septum. Another patient required placement of an Amplatzer device due to postprocedure embolization of the originally placed 25-mm Helex device. This case and the description of the method of retrieval have been previously reported [13].

**TABLE V. Patients with High Degree of Residual Shunting Who Required a Second Procedure and Placement of an Additional PFO Closure Device**

| Case number | Gender | Age | Reason for original referral | Atrial septal aneurysm | Index device     | Condition after the index procedure                      | Additional device          | Result  |
|-------------|--------|-----|------------------------------|------------------------|------------------|--|----------------------------|---|
| 1           | Male   | 67  | Orthodeoxia                  | No                     | Helex 30 mm      | Progressive deterioration of Sa O <sub>2</sub> into 70s  | Amplatzer ASO 15 mm        | Resolution of symptoms  |
| 2           | Male   | 73  | Cryptogenic Stroke           | Yes                    | CardioSeal 40 mm | Transient neurological symptoms, DVT, pulmonary embolism | Amplatzer Cribriform 25 mm | Resolution of neurological symptoms, prevention of recurrent stroke                   |
| 3           | Female | 50  | Migraine Headache            | No                     | CardioSeal 44 mm | Debilitating migraines, transient neurological symptoms  | Amplatzer ASO 10 mm        | Some improvement in migraine intensity, resolution of transient neurological symptoms |

Another three patients had a residual shunt after PFO closure with significant symptoms or risk which required a repeat procedure with placement of an additional occluder device (Table V). These examples are described in the following case series.

**CASE SERIES**

**Case 1**

The first patient was a 67-year-old male with a history of ascending aortic dissection who had his ascending aorta and aortic valve replaced with a Bentall procedure in 1997. He subsequently had expansion of his aortic arch aneurysm to 6 cm and was referred for endovascular repair.

As an initial stage, a right carotid to left carotid retropharyngeal bypass and a left carotid to left subclavian anastomosis were performed to free the aortic arch for subsequent endovascular repair. After surgery, the patient’s oxygen saturation decreased, possibly due to left hemidiaphragm paresis caused by surgical trauma to the left phrenic nerve. Following the surgery, he had shortness of breath with a decreased oxygen saturation level (baseline oxygen saturation was 88%) with orthodeoxia-platypnea. A PFO was found on transthoracic echocardiography (TTE) with bubble study; TCD demonstrated a grade 5+ shunt at rest, with innumerable microbubbles. Percutaneous PFO closure was attempted to improve the patient’s hypoxemia. The estimated PFO size was 15 mm based on the sizing balloon (Fig. 1A) and a 30-mm Helex device was deployed (Fig. 1B). Intracardiac echocardiography (ICE) confirmed the correct position of the device and intravenous agitated saline demonstrated a reduction of right-to-left shunting, although it was not completely occluded (Fig. 1C). Oxygen saturation increased to 98% on room air when the balloon crossed through the PFO and also after placement of the Helex device.

However, at 3 months postprocedure, the patient’s condition was unchanged from baseline. His oxygen saturation was only 74% on room air, and 94% while on 8 L/min of supplemental oxygen. A TEE demonstrated a large residual right-to-left shunt by color-flow Doppler and bubble study (Fig. 1D and E). TCD continued demonstrating a grade 5+ shunt. A second percutaneous procedure was attempted. During the procedure, a J-wire was passed with relative ease across the Helex device into the left superior pulmonary vein (Fig. 1F). An Amplatzer sizing balloon showed the dimension of the residual PFO tunnel measuring 15 mm in diameter (Fig. 1G). Using ICE and fluoroscopy, a 15-mm diameter ASO was advanced into the PFO alongside the original Helex device (Fig. 1H). A follow-up agitated saline bubble study showed decreased flow across the septum (Fig.

11). Two months after closure of the residual shunt, the patient's condition improved with his O<sub>2</sub> saturation at 96% on room air. The TCD Spencer grade decreased to grade 4 at rest and on Valsalva. The patient subsequently underwent endovascular repair of his aortic aneurysm without complication.

### Case 2

A 71-year-old man had a history of severe migraines and three strokes associated with a PFO presumably due to paradoxical embolism. The first stroke occurred at age 31, followed by a stroke at age 41 while on medical therapy. At age 63, he was diagnosed with a third small stroke by brain MRI. Consequently, transcatheter PFO closure was attempted using a 40-mm CardioSEAL device. Despite appropriate deployment, at 1 year follow-up, a residual shunt was seen by a bubble study using TTE. With double antiplatelet therapy and Coumadin, no further neurological events occurred and a repeat PFO closure was not attempted.

Six years later, following a long plane flight, the patient suffered deep venous thrombosis and pulmonary embolism. Although no symptoms of recurrent stroke were seen, there was a risk of a thrombus passing through the residual PFO canal into the arterial circulation. A repeat transcatheter PFO closure was performed. Figure 2A and B show baseline images; the arms of the CardioSEAL device protrude upward in patients with a long PFO tunnel and may retract over time. A bubble study confirmed that a large shunt was present from the right-to-left atrium through the CardioSEAL device. On TCD, the Spencer grade at rest was 5.

A standard J-wire was passed through the residual PFO (Fig. 2C). A 20-mm Helex device was inserted across the atrial septum under ICE and fluoroscopic guidance; however, the left atrial disk of the Helex was not covering the CardioSEAL device adequately. The 20-mm Helex device was retrieved and exchanged with a larger, 30-mm device, but this also did not successfully close the residual PFO.

Due to the rigidity of the CardioSEAL device, a 25-mm Amplatzer Cribiform occluder was chosen, which adequately covered the residual tunnel. ICE and fluoroscopy demonstrated that the Amplatzer device was well lodged within the CardioSEAL device (Fig. 2D). Three months after the procedure the Spencer grade dropped to grade 1 at rest and grade 2 on Valsalva. In addition, the migraines were significantly reduced in frequency and severity once the shunt was eliminated.

### Case 3

A 49-year-old woman had severe, debilitating migraine headaches. Her PFO was closed at an outside

institution with a 33-mm CardioSEAL device in 2008; therefore, baseline TCD assessment was not available. Her symptoms did not resolve and TEE demonstrated a large residual right-to-left shunt with Valsalva. In 2010, she was referred to UCLA for a second transcatheter PFO closure. At this time, a TCD was performed and was grade 5 at rest and on Valsalva.

A CardioSEAL device with vertically positioned prongs protruding into the right atrium was visualized by fluoroscopy (Fig. 3A) and ICE. Residual right-to-left shunting was identified through the PFO tunnel (color-flow Doppler on ICE, Fig. 3B). A 6-French multipurpose catheter with a 0.035" J-wire easily crossed the PFO and was placed in the left upper pulmonary vein. A 24-mm sizing balloon revealed a residual PFO tunnel approximately 15 mm in length and 6-mm wide (Fig. 3C). An 8-mm Amplatzer ASD occluder was deployed and appeared to cover the PFO. There was still shunting from the right-to-left atrium by ICE, so the 8-mm Amplatzer device was exchanged for a 10-mm Amplatzer device (Fig. 3D). Figure 3E demonstrates that the Amplatzer's right atrial disk was deployed between the CardioSEAL spider arms and the atrial septum. ICE with color-flow Doppler revealed no residual right-to-left shunt and the Amplatzer device was released. Three months after the procedure the TCD showed grade 0 at rest and on Valsalva. Despite adequate closure, the patient continued to have migraine headaches.

## DISCUSSION

Modern transcatheter PFO closure devices provide a less invasive alternative to cardiac surgery, demonstrating a high success rate. Previous studies have reported a successful closure rate of 93.8% at 6 months using the Amplatzer ASO device [14], 75–92% using the Amplatzer PFO occluder [15–17], 93.7% at mean follow-up of 12 months using the Amplatzer Cribiform occluder [18], 66.7% using the CardioSEAL device [19], and 81–96% using the Gore Helex device [20–22].

It is important to determine the size and type of device that is capable of adequately closing a PFO to achieve the desired clinical benefit. Variations in the length and width of the PFO tunnel, and the compliance of the tissue, are parameters that affect how different devices fit within the PFO canal. The choice of the original device is largely dictated by the anatomic morphology and size of the PFO. Unless the PFO is small by echo imaging, estimation of PFO size should be done using a balloon-sizing catheter, with device size generally chosen 1–2 mm larger than the measured diameter of the PFO tunnel using the self-centering



devices, or for the central pin devices, the diameter should be twice the width of the measured PFO.

In addition to the shape and diameter of the PFO defect, careful consideration should be given to the thickness of the septum secundum and excursion of the atrial septum. The Amplatzer PFO Occluder is designed to fit in a PFO, whereas all other devices currently used for PFO closure have been designed for ASD anatomy. The Amplatzer PFO is not available commercially in the United States but is being assessed in randomized clinical trials (RESPECT and PREMIUM). The Amplatzer PFO is more rigid compared to the other devices, which may be beneficial in some cases, but may be responsible for excessive scarring and chest discomfort experienced by some patients.

The Helex septal occluder is a non-self centering device that is an acceptable alternative to patients with intolerance to nickel, a condition that affects 10–15% of the adult population [23,24]. Compared to the Amplatzer device, the Helex device is more flexible and well tolerated with only 3% of patients complaining of chest discomfort after the procedure [25]. However, the compressive strength of the Helex device is limited and devices larger than 25 mm cannot provide a firm closure of large PFOs. Hammerstringl et al. found that the Helex device is an independent risk factor for residual shunting [26]. Von Bardeleben et al. also described significant differences of closure rates between Helex and Amplatzer devices of larger size [27].

The CardioSEAL and STARFlex devices were designed like a clamshell to clamp down on the atrial septum and close an ASD. Unlike an ASD, the PFO morphology is like a tunnel of variable length created by overlap of the septum primum and septum secundum. When the CardioSEAL device is used to close a PFO with a short tunnel, the arms of the device lie flat on the septum and effectively seal the PFO, especially as scar tissue grows between the dacron squares. However, when the septum secundum is thicker or the PFO tunnel is longer, the arms are held further apart (as in case 2 and 3). With time the arms retract, which may be due to scar tissue formation on the outside of the dacron squares. This results in recurrent shunting through the residual PFO defect.

The Cribriform Amplatzer device is designed for fenestrated ASDs. Similar to the CardioSEAL device, it can be used effectively for some PFOs, but also does not fit well in all anatomic variations of PFO, which may result in a moderate residual shunt.

The Amplatzer ASD device is not designed for PFO closure; however, when the PFO is wide, such as >12 mm, or if the septum primum is very compliant and stretchable as with an atrial septal aneurysm, then the

ASD Occluder fits very well and is very effective in resolving the right-to-left shunt.

When the residual shunt is large and the patient is symptomatic, it may be justified to place an additional device. Consideration should be given to the morphology of the residual PFO tunnel in relation to the existing device, as well as the size of the residual PFO tunnel. The additional device should have a firm fit in the canal and a relatively strong closure force. The Amplatzer ASD device appears to have the characteristics which are useful for the successful deployment of a second device.

## LIMITATIONS

This is a retrospective observational study; therefore, there is likely to be selection bias. As the patients were not randomized by the size of the defect, the results of the study may be skewed in favor of one of the devices.

Ideally, the results should be further studied in a randomized clinical trial. However, it is unlikely that there will be a direct comparison among these devices.

Another major limitation of our study is that the data were incomplete, with TCD being unavailable for 123 patients. In addition, the results of the TCD assessment do not always correlate with the results of cardiac catheterization, with 8% of TCDs being false negative [28]. Therefore, it is possible that some of the patients with a negative TCD in fact still had some degree of right-to-left shunting.

## CONCLUSIONS

Transcatheter PFO closure has a high success rate, but a moderate residual shunt occurs in about 10% of cases. PFO closure is most effective with the Amplatzer ASD device (100%), followed by the Amplatzer Cribriform (93%), Gore Helex (90%), Amplatzer PFO (86%), and CardioSEAL (86%) device. The incidence of residual shunting after PFO closure is significantly larger with the 30-mm Helex device compared to that of the 25 or 20 mm Helex sizes, or any of the Amplatzer devices.

The larger nonself-centered devices (e.g., Helex) should be avoided in patients with a large PFO defect >12 mm as they provide insufficient closure of the PFO tunnel. The management of residual shunting does not require surgical intervention and can be accomplished with placement of an additional Amplatzer ASD device.

## REFERENCES

1. Drighil A, El Mosalami H, Elbadaoui N, Chraibi S, Bennis A. Patient foramen ovale: A new disease? *Int J Cardiol* 2007;122: 1–9.

2. Handke M, Harloff A, Olschewski M, Hetzel A, Geibel A. Patent foramen ovale and cryptogenic stroke in older patients. *N Engl J Med* 2007;357:2262–2268.
3. Calvert PA, Rana BS, Kydd AC, Shapiro LM. Patent foramen ovale: Anatomy, outcomes, and closure. *Nat Rev Cardiol* 2011; 8:148–160.
4. Beelke M, Angeli S, Del Sette M, Gandolfo C, Cabano ME, Canovaro P, Nobili L, Ferrillo F. Prevalence of patent foramen ovale in subjects with obstructive sleep apnea: A transcranial Doppler ultrasound study. *Sleep Med* 2003;4:219–223.
5. Nagpal SV, Lerakis S, Flueckiger PB, Halista M, Willis P, Block PC, Douglas JS, Morris DC, Liff DA, Stewart J, Devireddy C, Veledar E, Nahab FB, Babaliaros VC. Long-term outcomes after percutaneous patent foramen ovale closure. *Am J Med Sci* 2013;346:181–186.
6. Wilmschurst P, Nightingale S. The role of cardiac and pulmonary pathology in migraine: A hypothesis. *Headache* 2006;46:429–434.
7. Papa M, Gaspardone A, Fragasso G, Ajello S, Gioffre G, Iamele M, Iani C, Margonato A. Usefulness of transcatheter patent foramen ovale closure in migraineurs with moderate to large right-to-left shunt and instrumental evidence of cerebrovascular damage. *Am J Cardiol* 2009;104:434–439.
8. Gu X, He Y, Li Z, Kontos MC, Paulsen WH, Arrowood JA, Nixon JV. Comparison of frequencies of patent foramen ovale and thoracic aortic atherosclerosis in patients with cryptogenic ischemic stroke undergoing transesophageal echocardiography. *Am J Cardiol* 2011;108:1815–1819.
9. Agarwal S, Bajaj NS, Kumbhani DJ, Tuzcu EM, Kapadia SR. Meta-analysis of transcatheter closure versus medical therapy for patent foramen ovale in prevention of recurrent neurological events after presumed paradoxical embolism. *JACC Cardiovasc Interv* 2012;5:777–789.
10. Homma S, Sacco RL. Patent foramen ovale and stroke. *Circulation* 2005;112:1063–72.
11. Wohrle J. Closure of patent foramen ovale after cryptogenic stroke. *Lancet* 2006;368:350–352.
12. Spencer MP, Moehring MA, Jesurum J, Gray WA, Olsen JV, Reisman M. Power m-mode transcranial Doppler for diagnosis of patent foramen ovale and assessing transcatheter closure. *J Neuroimaging* 2004;14:342–349.
13. Poommipanit P, Levi D, Shenoda M, Tobis J. Percutaneous retrieval of the locked Helex septal occluder. *Catheter Cardiovasc Interv* 2011;77:892–900.
14. Krasnigi N, Roth J, Siegrist PT, Toggweiler S, Gruner C, Greutmann M, Tanner FC, Luscher TF, Corti R. Percutaneous closure of patent foramen ovale and valvular function—effect of the amplatzer occluder. *J Invasive Cardiol* 2012;24:274–277.
15. Wahl A, Tai T, Praz F, Schwerzmann M, Seiler C, Nedeltchev K, Windecker S, Mattle HP, Meier B. Late results after percutaneous closure of patent foramen ovale for secondary prevention of paradoxical embolism using the Amplatzer PFO occluder without intraprocedural echocardiography: Effect of device size. *JACC Cardiovasc Interv* 2009;2:116–123.
16. Spies C, Reissmann U, Timmermanns I, Schrader R. Comparison of contemporary devices used for transcatheter patent foramen ovale closure. *J Invasive Cardiol* 2008;20:442–447.
17. Bilkowski J, Wawrzynczyk M, Karwot B, Fiszer R, Knop M, Szkutnik M. Medium-term results of transcatheter closure of patent foramen ovale (PFO) with Amplatzer PFO and Cribiform occluders. *Kardiologia Pol* 2012;70:1142–1146.
18. Rigatelli G, Dell'Avvocata F, Cardaioli P, Braggion G, Giordan M, Mazza A, Fraccaro C, Chinaglia M, Chen JP. Long-term results of the amplatzer cribiform occluder for patent foramen ovale with associated atrial septal aneurysm: Impact on occlusion rate and left atrial functional remodelling. *Am J Cardiovasc Dis* 2012;2:68–74.
19. Tande AJ, Knickelbine T, Chavez I, Mooney MR, Poulouse A, Harris KM. Transseptal technique of percutaneous PFO closure results in persistent interatrial shunting. *Catheter Cardiovasc Interv* 2005;65:295–300.
20. Ponnuthurai FA, van Gaal WJ, Burchell A, Wilson N, Ormerod O. Single centre experience with GORE-HELEX septal occluder for closure of PFO. *Heart Lung Circ* 2009;18:140–142.
21. Billinger K, Ostermayer SH, Carminati M, Degiovanni JV, Ewert P, Hess J, Maymone-Martins FA, Qureshi SA, Salmon AP, Schneider M, Wilson N, Sievert H. HELEX septal occluder for transcatheter closure of patent foramen ovale: Multicentre experience. *EuroIntervention* 2006;1:465–471.
22. Heinisch C, Bertoq S, Wunderlich N, Majunke N, Baranowski A, Leetz M, Fischer E, Staubach S, Zimmermann W, Hofmann I, Sievert H. Percutaneous closure of the patent foramen ovale using the HELEX® Septal Occluder: acute and long-term results in 405 patients. *EuroIntervention* 2012;8:717–723.
23. Rabkin DG, Whitehead KJ, Michaels AD, Powell DL, Karwande SV. Unusual presentation of nickel allergy requiring explantation of an Amplatzer atrial septal occluder device. *Clin Cardiol* 2009;32:E55–E57.
24. Verma SK, Tobis JM. Explantation of patent foramen ovale closure devices: A multicenter survey. *JACC Cardiovasc Interv* 2011;4:579–585.
25. Musto C, Cifarelli A, Fiorilli R, De Felice F, Parma A, Pandolfi C, Confessore P, Bernardi L, Violini R. Gore Helex septal occluder for percutaneous closure of patent foramen ovale associated with atrial septal aneurysm: short- and mid-term clinical and echocardiographic outcomes. *J Invasive Cardiology* 2012; 24:510–514.
26. Hammerstringl C, Bauriedel B, Stusser C, Momcilovic D, Tuleta I, Nickenig G, Skowasch D. Risk and fate of residual interatrial shunting after transcatheter closure of patent foramen ovale: A long term follow up study. *Eur J Med Res* 2011;16:13–19.
27. von Bardeleben RS, Richter C, Otto J, Himmrich L, Schnabel R, Kampmann C, Rupperecht HJ, Marx J, Hommel G, Munzel T, Horstick G. Long term follow up after percutaneous closure of PFO in 357 patients with paradoxical embolism: Difference in occlusion systems and influence of atrial septum aneurysm. *Int J Cardiol* 2009;134:33–41.
28. Gevorgyan R, Perkowski A, Shenoda M, Mojadidi MK, Agrawal H, Tobis JM. Sensitivity of brachial versus femoral vein injection of agitated saline to detect right-to-left shunts with transcranial doppler. *Catheter Cardiovasc Interv* 2014. doi: 10.1002/ccd.25391. [Epub ahead of print]