

UC Irvine

Western Journal of Emergency Medicine: Integrating Emergency Care with Population Health

Title

Evaluation and Management of Angioedema in the Emergency Department

Permalink

<https://escholarship.org/uc/item/9cr1m7qq>

Journal

Western Journal of Emergency Medicine: Integrating Emergency Care with Population Health, 20(4)

ISSN

1936-900X

Authors

Long, Brit Jeffrey
Koyfman, Alex
Gottlieb, Michael

Publication Date

2019

DOI

10.5811/westjem.2019.5.42650

Copyright Information

Copyright 2019 by the author(s). This work is made available under the terms of a Creative Commons Attribution License, available at <https://creativecommons.org/licenses/by/4.0/>

Peer reviewed

Evaluation and Management of Angioedema in the Emergency Department

Brit Jeffrey Long, MD*
 Alex Koyfman, MD†
 Michael Gottlieb, MD‡

*Brooke Army Medical Center, Department of Emergency Medicine, Fort Sam Houston, Texas

†The University of Texas Southwestern Medical Center, Department of Emergency Medicine, Dallas, Texas

‡Rush University Medical Center, Department of Emergency Medicine, Chicago, Illinois

Section Editor: Kenneth Whitlow, DO

Submission history: Submitted February 3, 2019; Revision received May 9, 2019; Accepted May 28, 2019

Electronically published July 2, 2019

Full text available through open access at http://escholarship.org/uc/uciem_westjem

DOI: 10.5811/westjem.2019.5.42650

Angioedema is defined by non-dependent, non-pitting edema that affects several different sites and is potentially life-threatening due to laryngeal edema. This narrative review provides emergency physicians with a focused overview of the evaluation and management of angioedema. Two primary forms include histamine-mediated and bradykinin-mediated angioedema. Histamine-mediated forms present similarly to anaphylaxis, while bradykinin-mediated angioedema presents with greater face and oropharyngeal involvement and higher risk of progression. Initial evaluation and management should focus on evaluation of the airway, followed by obtaining relevant historical features, including family history, medications, and prior episodes. Histamine-mediated angioedema should be treated with epinephrine intramuscularly, antihistaminergic medications, and steroids. These medications are not effective for bradykinin-mediated forms. Other medications include C1-INH protein replacement, kallikrein inhibitor, and bradykinin receptor antagonists. Evidence is controversial concerning the efficacy of these medications in an acute episode, and airway management is the most important intervention when indicated. Airway intervention may require fiberoptic or video laryngoscopy, with preparation for cricothyrotomy. Disposition is dependent on patient's airway and respiratory status, as well as the sites involved. [West J Emerg Med. 2019;20(4)587-600.]

INTRODUCTION

Angioedema is a condition defined by non-dependent, non-pitting, transient edema lasting up to seven days due to the accumulation of vasoactive substances.¹⁻⁵ These substances increase vascular permeability, resulting in swelling in the deep dermal, submucosal, and subcutaneous tissues of the face, lips, neck, extremities, and gastrointestinal (GI) system.^{1,2,6-9} Urticaria may be present in up to 50% of cases, depending on the underlying process.^{1,2,6-9}

Angioedema accounts for 80,000 to 112,000 emergency department (ED) visits per year, with a hospitalization rate of 4.0 per 100,000 population.¹⁰⁻¹² For patients taking angiotensin-converting enzyme inhibitors (ACEi), the incidence of angioedema ranges from 0.1-0.7% over a patient's lifetime, while the prevalence of hereditary angioedema (HAE) ranges from 1 in 10,000 to 1 in 50,000 persons.^{6,10-15} Over 50% of patients with HAE require ED management, with over half of

patients admitted to the hospital.¹⁻³ ACEi-mediated angioedema accounts for 30% of angioedema cases. Of the cases of ACEi-mediated angioedema, one study found 18% of patients were admitted to observation, 12% to the inpatient setting, and 11% to the intensive care unit.^{1,16} Due to risk of airway involvement and death, the emergency physician (EP) plays a key role in assessment and management of angioedema.^{1,2,17,18}

METHODS

We searched PubMed and Google Scholar for articles in English from 1966 to October 2018 using a combination of the keyword and medical subject heading "angioedema" for production of this narrative review. Our search included case reports and series, retrospective and prospective studies, systematic reviews and meta-analyses, narrative reviews, and clinical guidelines. Two authors decided by consensus which studies to include for the review. Initial literature search revealed

over 500 articles, of which 185 were selected for inclusion, focusing on ED evaluation and management.

DISCUSSION

Etiology

Angioedema can be defined as either hereditary (bradykinin) or acquired (bradykinin or histamine) (Table 1).^{1-5,7,15,19-24} The underlying pathophysiology (ie, bradykinin- vs histamine-mediated) influences the clinical presentation and treatment recommendations.^{1,2,7,8} Bradykinin-mediated forms are generally more severe, longer lasting, and frequently involve the upper airway and gastrointestinal (GI) system.^{1,20-24}

Histamine-mediated

Histamine-mediated angioedema is the most common form, accounting for 40-70% of all cases, and is associated with immunoglobulin E resulting in degranulation of mast cells and basophils.¹⁻⁵ H1 and H2 receptors are primarily responsible for the swelling that leads to angioedema.^{1,4,5} Histamine-mediated angioedema, such as anaphylaxis, occurs rapidly after an allergen exposure (type I hypersensitivity reaction).^{5,25-30} Histamine-mediated angioedema and anaphylaxis present similarly, as they are along the same clinical spectrum, although diagnosis of anaphylaxis requires specific clinical criteria.¹⁻⁵ Importantly, therapy for histamine-mediated angioedema and anaphylaxis is the same, which will be discussed later. Histamine-mediated angioedema typically resolves within 24-48 hours. This form can result from food allergens, medications, exercise, bites, stings, or latex exposure.³¹⁻³³ There is also a form of physically-induced angioedema from cold exposure, heat pressure, physical activity, ultraviolet radiation, and vibration, which is most likely due to histamine release.³⁴⁻³⁶

Population Health Research Capsule

What do we already know about this issue?
Angioedema is defined by non-dependent, non-pitting edema that affects several different sites and is potentially life-threatening due to laryngeal edema.

What was the research question?
This narrative review evaluates the pathophysiology, evaluation, and management of angioedema.

What was the major finding of the study?
There are two forms of angioedema. Management must focus on the airway, although several medications are promising.

How does this improve population health?
Evidence is controversial for the efficacy of several medications, and airway management is the most vital intervention if indicated. Disposition depends upon airway and respiratory status.

Bradykinin-mediated

Bradykinin-mediated pathways involve this vasoactive nonapeptide that activates endothelial cells.^{5,14,37} Several systems regulate bradykinin, including the coagulation, complement, and contact pathways.^{4,38} Excess bradykinin is due to production, release, or inhibition of its breakdown.³⁹⁻⁴¹ This form comprises drug-induced angioedema (ie, ACEi-mediated), HAE

Table 1. Types of angioedema.

Types	Characteristics
Histamine-mediated (with urticaria)	- Allergy to food, venom, latex, medication - Acute or chronic spontaneous urticaria - Urticaria/angioedema associated with cold urticaria, vasculitis, exercise, episodic angioedema, vibration-induced, drug reaction
Bradykinin-mediated (without urticaria)	- Type I HAE: defective C1-INH level/function - Type II HAE: defective C1-INH function - Type III HAE: normal C1-INH -Acquired C1-INH deficiency: Type I associated with increased catabolism of C1-INH (lymphoproliferative disorder, autoimmune disease); Type II associated with autoantibody to C1-INH - ACEi-mediated angioedema - Medication associated: dipeptidyl peptidase-IV inhibitor (gliptins for diabetes mellitus), angiotensin II receptor blockers, recombinant tissue plasminogen activator, sirolimus, tacrolimus, everolimus
Idiopathic (unknown etiology)	- Histaminergic - Nonhistaminergic

HAE, hereditary angioedema; C1-INH, C1 inhibitor; ACEi, angiotensin-converting enzyme inhibitor.

types I and II, and several forms of acquired and idiopathic angioedema.^{13,20,42,43}

ACEi-mediated angioedema accounts for up to 30% of ED visits for angioedema of all types.^{16,21,44-49} ACEis prevent the conversion of angiotensin I to angiotensin II and reduce bradykinin metabolism, which increases the risk of angioedema. Most cases are localized to the lips and tongue.^{14,15} Patients at greatest risk for developing ACEi-mediated angioedema include African Americans and those taking immunosuppressants or dipeptidyl peptidase-IV inhibitors (a class of diabetic medications) in addition to the ACEi.^{14,15,49} The rate of angioedema is highest within the first 30 days of starting an ACEi, although the risk of angioedema remains for the duration of the ACEi use, with cases of ACEi-mediated angioedema documented in patients with prolonged courses of multiple years.⁵⁰⁻⁵² If a patient continues taking an ACEi after developing ACEi-mediated angioedema, the average time to recurrence is approximately 10 months.^{50,53} Angiotensin II receptor blockers (ARB) and renin antagonists can also cause angioedema, but this is not due to bradykinin.¹⁻⁵ If angioedema develops in a patient on an ACEi, the ACEi should be discontinued and a different antihypertensive class used.

HAE is thought to be autosomal dominant with abnormal C1-INH amounts and/or function. HAE affects approximately 1 in 10,000–50,000 people.^{1,2,54,55} Type I is due to decreased and defective C1-INH and is the most common (85%) form of HAE, followed by type II which is caused by dysfunctional C1-INH.^{13,55-59} A third form of HAE with normal C1-INH has also been described.⁶⁰⁻⁶² Most patients present by age 10 with recurrent episodes of edema.^{1-4,58} HAE is often associated with prodromal symptoms, such as erythema marginatum, but not urticaria.^{1,4,16,61,63} HAE occurs more commonly in females and causes more severe swelling with significant face and tongue involvement when compared with males.^{1-5,13} Estrogen-containing medications and pregnancy increase the attack frequency in female patients.^{7,61,64}

Acquired angioedema appears similar to HAE with C1-INH deficiency, but this is not hereditary and more commonly affects those > 40 years.^{1,65-71} This form is most commonly due to catabolism of C1-INH, although some patients may have a lymphoproliferative or autoimmune disorder.^{1,65-71}

A less common cause of non-histaminergic angioedema is associated with medications, including nonsteroidal anti-inflammatory drugs (NSAID), antibiotics, and ARB.⁷²⁻⁷⁵ NSAID-associated angioedema results from inhibition of cyclooxygenase and accumulation of leukotriene mediators, and occurs in 0.1-0.3% of patients taking an NSAID.⁵⁶ Exposure to recombinant tissue plasminogen activator therapy in acute ischemic stroke is also associated with angioedema, occurring in 1.2-5.1% of patients, with increased risk in patients taking an ACEi.⁷⁶⁻⁸⁰ Most of these cases are mild and resolve in 24 hours.^{1,2,7,8}

Idiopathic

Idiopathic angioedema is diagnosed by failure to determine

the etiology with ≥ 3 attacks in a 6-12 month period.^{2,5,81-83} Most patients with idiopathic angioedema will demonstrate a response to standard therapies for anaphylaxis (eg, epinephrine, antihistamines, steroids), although a small group will not improve with these therapies.^{1-4,84} This latter group is more commonly bradykinin-associated.^{1-4,84}

Presentation, History, and Physical Examination

Initial evaluation requires assessing vital signs, airway, and cardiovascular systems. Asphyxiation is the leading cause of mortality in these patients, necessitating airway evaluation.^{17,18,85} At least one episode of laryngeal edema occurs in over half of all patients with HAE and accounts for over 30% of deaths in HAE.^{17,18} Emergency physicians (EP) must inquire about lip swelling, tongue swelling, and GI symptoms (nausea, vomiting, diarrhea, and pain). Additional information to gather includes prior personal or family history of angioedema, medications, and related symptoms (eg, pruritis, dyspnea, syncope, lightheadedness).⁸⁵⁻⁹³ Patients with a known history of HAE should also be asked about recent trauma, which can trigger an episode.¹⁻⁵ Most patients with HAE report prodromal symptoms prior to swelling, such as fatigue and rash.⁹⁴

The presentation can vary depending upon the subtype but is primarily dependent upon whether the etiology is histaminergic or non-histaminergic (Table 2).^{1-5,13} The most commonly involved areas include the head and neck (eg, eyelids, lips, tongue, larynx), extremities (eg, hands and feet), external urogenital system, and abdomen.^{1-5,9,13,28} However, involvement of these sites is often non-contiguous, with no specific pattern.^{1-5,7,8} Histaminergic forms display faster onset, while HAE and acquired forms have a slower, progressive onset occurring over several hours.^{1,2,7,8} GI tract submucosal involvement occurs in up to 93% of patients with HAE and can cause symptoms that mimic bowel obstruction.^{13,55,90,91} Non-pitting edema is present in both histaminergic and non-histaminergic forms.^{1,4,7,8} Pruritic, localized, urticarial lesions may be present in histamine-mediated forms with involvement

Table 2. Comparison of features between non-histaminergic and histaminergic angioedema.

Features	Histaminergic	Non-histaminergic
Onset	Minutes	Hours
Duration	12-24 hours	48-72 hours
Hypotension	Common	Atypical
Urticaria	Common	Atypical
Bronchospasm; wheezing	Common	Atypical
Laryngeal edema	Possible	Possible
Abdominal pain	Possible	Possible
Therapy with epinephrine, antihistamines, steroids	Effective	Not effective

of the deep dermis, but these are rare in non-histaminergic forms.^{13,95,96} Urticaria occurs in approximately 50% of patients with histamine-mediated angioedema.^{13,95,96}

Findings suggestive of the need for a definitive airway include stridor, hoarseness, dyspnea, and voice changes.⁸⁶⁻⁹² The patient should be asked to phonate “E” with a high pitch, as a patient able to complete this maneuver is unlikely to have laryngeal edema.^{1,7,8} Auscultation of the lungs to determine the presence of wheezing is recommended.

Differentiating histamine and bradykinin-mediated angioedema can be difficult. One retrospective study evaluated 188 patients, with one point assigned to age > 65 years, dyspnea, no itching or erythema, laryngeal involvement, and intake of ACEi/AT-II antagonist, and two points assigned if there was no response to steroid therapy.⁹⁷ If the score was ≥ 3 points, the patient was treated with C1-INH or B2 receptor antagonist for suspicion of bradykinin-mediated angioedema. This resulted in a sensitivity of 96% and specificity of 84% for the diagnosis of bradykinin-mediated angioedema.⁹⁷ While this tool can help to differentiate the underlying etiology, it requires further validation before routine use.

Diagnostic Testing

Angioedema is a clinical diagnosis, with no required testing in the ED.^{1,2,4} Leukocyte counts cannot reliably differentiate if an infection is present, as leukocytosis over 30,000 per cubic millimeter has been observed.⁹⁸ C-reactive protein may be elevated in ACEi-mediated angioedema.^{1,4} Determining the specific type of angioedema involves specialized laboratory testing not available in the ED, including tryptase, C4, and C1-INH.^{1,4} These tests can be obtained in the outpatient setting and should not be routinely obtained in the ED, as they do not guide management. Histamine-mediated forms can display elevated tryptase levels during attacks, while patients with HAE will display normal tryptase levels.³ C4 levels serve as a sensitive screening test for C1-INH deficiency.^{1,3} Serum C4 levels will typically be < 30% of normal in acute episodes of angioedema from HAE types I and II, although the laboratory values may be normal between attacks.^{23,100,101} Type I HAE often involves low C1-INH levels and decreased function, while type II HAE includes normal levels but decreased function.^{13,19,102} C1q levels, a component of the complement system, can be used to differentiate acquired and hereditary forms, as C1q is decreased in acquired angioedema and normal in HAE.^{1,3,4,100,103} Type III HAE has normal levels and function of C1-INH but is usually identified by a positive family history.^{1-4,7,8} No tests can confirm ACEi-mediated angioedema.^{1,7,19,23}

Patients with abdominal symptoms may demonstrate segmental bowel wall edema, straightening of intestinal segments, and ascites on computed tomography (CT).^{4,104,105} Ultrasound may similarly reveal bowel wall thickening or ascites.¹⁰⁶ Ultrasound can be used to evaluate for laryngeal edema, although this requires further study.⁴ Chest radiography, if obtained, is typically normal. Neck radiographs and CT of

the neck with intravenous (IV) contrast can evaluate for mimics of angioedema, but they should not be ordered routinely for patients with suspected angioedema.¹⁰⁴ Fiberoptic visualization of laryngeal and airway structures is recommended if concern for laryngeal or airway involvement is present.

Management

The primary focus of ED management is assessment of the airway and evaluation for anaphylaxis, which is the most common mimic.^{1-4,7,8} Figure 1 depicts an algorithm for management. Vital signs should not be relied upon in isolation to determine the need for airway intervention.

Airway Management

Patients with angioedema involving the tongue or larynx require consideration of definitive airway management. Angioedema can progress rapidly within hours, and airway obstruction occurs in up to 15% of patients with angioedema.^{1,4,17,18} For patients with angioedema who require a definitive airway, cricothyrotomy or tracheostomy is needed in up to 50% of cases.^{17,87,105} Prior history of intubation or severe angioedema should raise the concern for a difficult airway which may require early airway intervention.^{1,4,107} Evidence of upper airway involvement on examination includes stridor, change in patient voice, and hoarseness. If physical examination reveals swelling of the tongue, floor of the mouth, or soft palate, directly visualize the tongue base and airway with fiberoptics. The presence of epiglottic, aryepiglottic, or laryngeal edema suggests need for definitive airway.^{1,2} If the angioedema exclusively involves structures anterior to the teeth such as the lips, intubation is generally not needed.⁸⁵⁻⁹²

Noninvasive positive pressure ventilation can also assist with temporization; however, this is not a definitive therapy for patients with airway involvement. Supraglottic and extraglottic airway devices are common rescue devices; however, they are not recommended in patients with angioedema, as the device will remain above the site of airway obstruction.^{1,4,7,8,85} If placed, these devices may also worsen edema due to the associated trauma with placement.

Physical manipulation of the airway may worsen edema, especially in bradykinin-mediated angioedema.^{1,4,7,8} In patients with history or evidence on examination of a difficult airway, video laryngoscopy or fiberoptic awake intubation is recommended, as this allows the patient to maintain his/her airway reflexes during airway visualization and the intubation attempt.^{1,4,107-109} Topical anesthetics and ketamine are optimal agents for awake intubation. Severe edema may prohibit passage of an endotracheal tube through the glottis, even with the use of fiberoptic or video laryngoscopy guidance. Thus, the resuscitation team must prepare for cricothyrotomy before an attempt at intubation is started, known as a double setup.¹⁻⁵ If the patient does not require immediate airway intervention, transfer to the operating room may be beneficial with anesthesia and otolaryngology consultation, similar to pediatric epiglottitis.

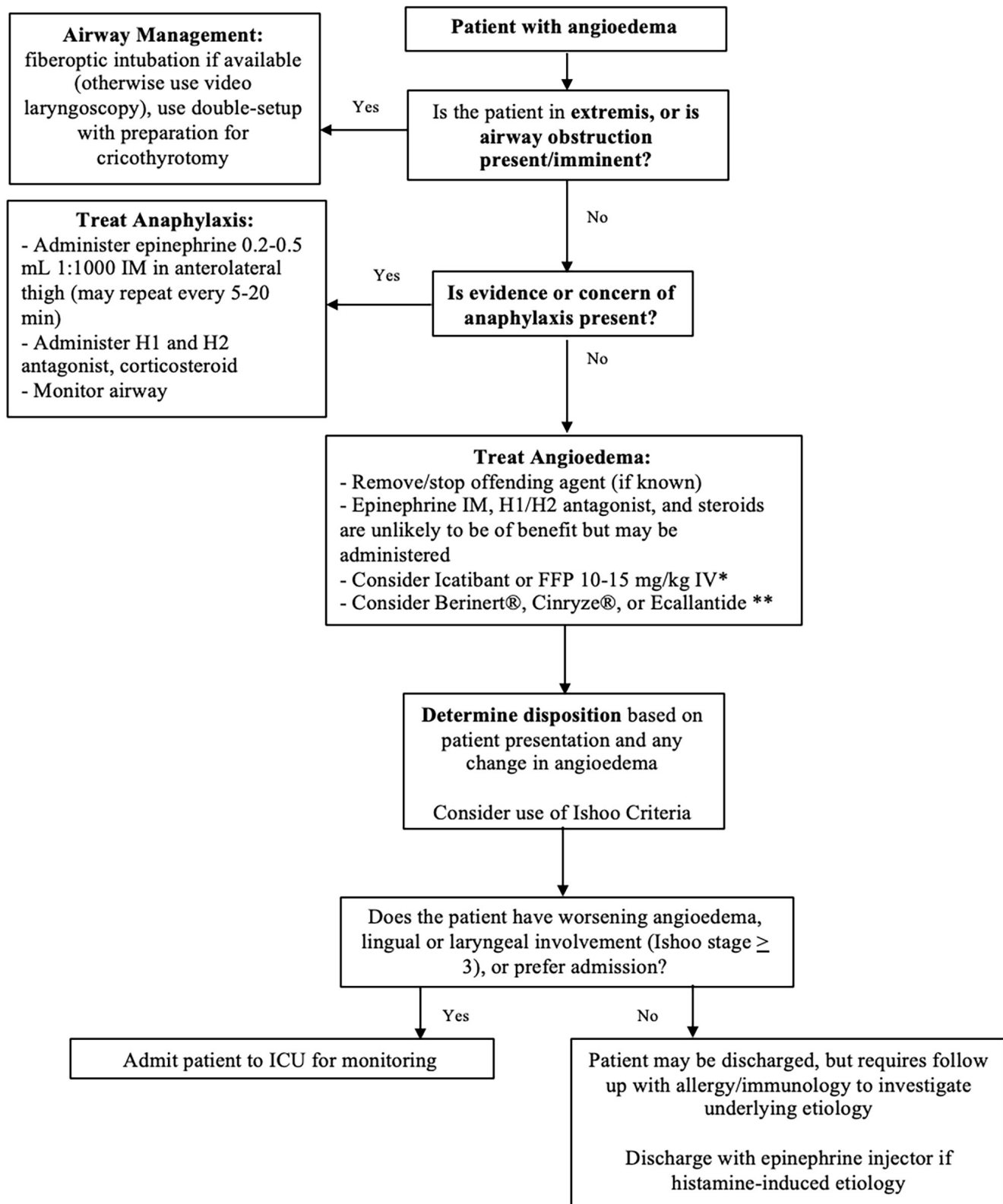


Figure 1. Algorithm for angioedema management.

IV, intravenous; *IM*, intramuscular; *ACEi*, angiotensin converting enzyme inhibitor; *FFP*, fresh frozen plasma; *ICU*, intensive care unit.

*ACEi-mediated, Hereditary, or Acquired Angioedema only.

**Hereditary or Acquired Angioedema only.

Medications

Medication management focuses on three aspects: acute episode management, short-term prophylaxis, and long-term prophylaxis, with ED management focusing on the acute episode.^{1,4,7,8} If the suspected etiology is drug- or allergic-induced, the trigger must be removed.¹⁻⁵ In histamine-mediated forms of angioedema, standard therapy for anaphylaxis is recommended. However, in other forms of angioedema including bradykinin-mediated forms, standard therapies for anaphylaxis should not be effective.^{110,111}

Patients with evidence of histaminergic forms of angioedema and concern for airway involvement should receive epinephrine, steroids, antihistamines, and IV fluids.^{1-5,7,8,112} If there is any suspicion of anaphylaxis, urticaria-associated angioedema, or if the exact underlying cause of the angioedema is unknown, histamine-mediated edema should be assumed. Epinephrine should be administered via the intramuscular route into the anterolateral middle third of the thigh, with initial dose 0.3-0.5 milliliter (mL) (0.3-0.5 milligram [mg]) of 1:1000 dilution (1 mg/mL), which can be repeated every 5-20 minutes.^{1,4} Subcutaneous administration is not recommended.¹¹²⁻¹¹⁴ IV epinephrine should be considered in patients requiring multiple doses of intramuscular epinephrine and should begin at doses of 1-4 micrograms (mcg) per minute.^{112,115,116} Epinephrine can be administered peripherally by injecting 1 mg of epinephrine into 1 L of normal saline, resulting in a final concentration of 1 mcg/mL. If administered wide-open through an 18-gauge IV, this provides 20-30 mL/minute (20-30 mcg/minute) of epinephrine.

Adjunctive therapies for histamine-mediated angioedema include antihistamines and steroids.^{1-5,7,8,112} Antihistamines have a slower onset of action and should only be used as an adjunctive therapy.^{1-5,7,8,112,117} Diphenhydramine is an H1 antagonist that can be used in doses of 25-50 mg IV to reduce swelling in combination with a second- or third-generation antihistamine agent (eg, cetirizine, loratadine, fexofenadine, levocetirizine, desloratadine).^{1-5,112,117-127} The addition of an H2 antagonist is beneficial in decreasing urticaria, as 15% of cutaneous histamine receptors are H2.¹¹⁷⁻¹²⁸ Steroids such as methylprednisolone 125 mg IV decrease inflammatory mediators in histamine-mediated angioedema and anaphylaxis but, similar to other medications, there is little to no evidence for their use in non-histaminergic angioedema.^{1,4,7,8,112} The onset of action after administration is delayed, typically requiring 4-6 hours to take effect.^{1-5,7,8,14,15}

Fresh frozen plasma (FFP) has been recommended for use in angioedema based on case reports demonstrating improvement in HAE and ACEi-mediated angioedema,¹²⁹⁻¹³³ as FFP contains varying amounts of C1-INH.^{1-4,7,8,14,15,134-136} Several of the first case reports suggested FFP can be used as prophylaxis for HAE in patients undergoing dental procedures.^{129,135,137} A retrospective study suggests efficacy in decreased intubation frequency and intensive care unit (ICU) length of stay.¹³⁷ However, type II HAE may worsen with FFP due to the presence of an autoantibody responsible for decreased C1-INH.¹³⁴ Limited literature has described FFP in ACEi-mediated angioedema, primarily case

reports and series demonstrating improved symptoms at four hours.^{132,133,136,138-145} Its use in acquired forms has not demonstrated efficacy, and a major limitation is the need to thaw FFP for use. The literature is inconsistent with regard to preferred dosing, with most studies giving 1-4 units (250-1000 cubic centimeters).^{1-5,135,136} FFP requires close to 50 times the volume of other medications with C1INH to obtain the same serum levels of enzyme.¹³⁵ Risks include potential volume overload, transmission of bloodborne infection, and hypersensitivity reaction.^{1-4,7,8,136} FFP also contains substrates such as kallikrein and kininogen that may paradoxically worsen angioedema.^{1-4,7,8,14} Despite this theoretical effect, worsening of angioedema with FFP administration has not been found in cases of ACEi-mediated angioedema.^{1,4,134-136} There is no support for FFP in other acquired forms of angioedema.^{1-4,135}

Prothrombin complex concentrate (PCC) has also been used for ACEi-mediated angioedema.^{1,4,146} However, the data is limited to one case report in which 1500 units were administered. Symptoms began to improve in 20 minutes, with resolution in eight hours.¹⁴⁶ Four-factor PCC contains C1-INH, which may explain the improved symptoms.

Targeted Therapies for Bradykinin-mediated Angioedema

Bradykinin-mediated forms of angioedema are typically resistant to therapies effective in histamine-mediated reactions.^{1,4,7,8,13,135,136,147} At the time of construction for this review, several medications have been FDA approved for treatment of acute bradykinin-mediated angioedema: three C1-INH concentrates (two plasma-derived and one recombinant), one kallikrein inhibitor, and one bradykinin-2-receptor antagonist (Table 3).^{1,4,7,8,13,135,136}

C1 Inhibitor Concentrate

C1-INH concentrate for HAE episodes was first described in 1973, and there are two plasma-derived formulations currently available (Berinert and Cinryze), as well as one recombinant form (Ruconest), all administered intravenously.^{1-5,7,8,135,136,148} They are currently approved for acute HAE, although these medications have been used for ACEi-mediated forms.^{1-5,7,8,135,136,148} Berinert and Cinryze provide native plasma protein that regulates kallikrein and Factor XII activity, reducing bradykinin production. Bork et al. published a study based on 18 patients with 193 episodes of HAE, finding that the mean time to reversal was 42.2 minutes.¹⁴⁹ The IMPACT trials (funded by CSL Behring, manufacturer of Berinert) evaluated Berinert vs placebo for acute episodes of HAE. IMPACT-1 found 20 units per kilogram (kg) improved time to symptom relief (0.5 hours vs 1.5 hours), but 10 units/kg did not.^{150,151} IMPACT-2 evaluated 1085 episodes of HAE in 57 patients, with a median time to symptom relief of 0.46 hours in patients receiving open-label Berinert.¹⁵¹ Cinryze has also been evaluated in HAE, with a double-blind placebo-controlled trial of 68 patients finding no statistically significant improvement in time to relief, although a double-blind crossover trial of 21 patients demonstrated decrease in attack number, duration, and severity.^{4,136,152} A study that was

Table 3. Angioedema medications.

Medication (trade name)	Mechanism	Route	Dose	Time to onset	Minor side effects	Serious side effects
Plasma derived C1-INH (Berinert, Cinryze)	C1-INH protein replacement	IV	Berinert 20 units/kg; Cinryze 1000 units	Median 30-48 minutes	Dysgeusia	Hypersensitivity, thrombosis, blood-borne infection
Recombinant C1-INH (Ruconest)	C1-INH protein replacement	IV	50 units/kg	Median 90 minutes	Pruritis, rash, sinusitis	Hypersensitivity, anaphylaxis
Ecallantide (Kalbitor)	Kallikrein inhibitor	SQ	30 mg	Median 67 minutes	Headache, injection site reactions, nausea, fever	Hypersensitivity, anaphylaxis
Icatibant acetate (Firazyr)	Bradykinin B2 receptor antagonist	SQ	30 mg	Median 2 hours	Elevated LFTs, injection reaction, dizziness, headache, nausea, fever	Theoretical worsening of an ongoing ischemic event
Fresh frozen plasma	C1-INH protein replacement (various amounts)	IV	15 mg/kg	Minutes to hours		Hypersensitivity, worsening angioedema, transfusion infection

C1-INH, C1 inhibitor; IV, intravenous; SQ, subcutaneous; LFTs, liver function tests; mg, milligram; kg, kilogram.

not placebo controlled found 68% of patients had improvement at one hour, while 87% experienced relief at four hours.¹⁵³ Other trials evaluating Berinert and Cinryze for HAE and ACEi-mediated angioedema have found that the time to symptom improvement from administration varies from 0.5-5 hours, with complete resolution occurring within 1-10 hours.¹³⁶ Ruconest is a recombinant form of C1INH. One open-label study with no placebo control found time to symptom relief of 30 minutes.¹⁵⁴ A double-blind, placebo-controlled trial found time to symptom relief of 66 minutes in patients receiving 100 units/kg, vs 495 minutes in controls.¹⁵⁵ Another randomized trial found time to symptom relief of 75 minutes in treated patients vs 303 minutes in patients receiving placebo.¹⁵⁶

Kallikrein Inhibitor

Ecallantide (Kalbitor) is a recombinant plasma inhibitor of kallikrein provided subcutaneously and approved for use in HAE.^{1,4,7,8,136} This agent reduces bradykinin synthesis by preventing the cleavage of kininogen.^{1,4,7,8,136} It is associated with up to a 3% risk of anaphylaxis, necessitating close observation during administration and for up to one hour after.^{1,4,7,8} The EDEMA trials evaluated ecallantide for HAE.¹⁵⁷⁻¹⁶⁰ The EDEMA1 trial evaluated ecallantide at various doses vs placebo, finding the 40 mg/m² dose improved symptoms at four hours, although other doses did not.¹⁵⁷ The phase 2 EDEMA2 trial found subcutaneous dosing had improved outcomes vs IV dosing.¹⁵⁸ EDEMA3 was an open label and double-blind phase 3 trial evaluating ecallantide vs placebo, with improvement in treatment score at four hours in patients receiving ecallantide.¹⁵⁹ EDEMA4 found improved symptom scores vs placebo.¹⁶⁰ A triple-blind phase 2 randomized controlled trial compared ecallantide at three different subcutaneous doses with placebo for ACEi-mediated

angioedema and found no difference in patients meeting criteria for discharge.¹⁶¹ Lewis et al. conducted a double-blind phase 2 study with patients randomized to placebo or ecallantide.¹⁶² Most patients received therapy for histamine-mediated angioedema as well. The study found no difference in patients meeting criteria for discharge within six hours with ecallantide administration.¹⁶²

Bradykinin B2 Receptor Antagonist

Icatibant acetate (Firazyr) is a selective and competitive bradykinin B2 receptor antagonist.^{1,4,7,8,136} Icatibant was evaluated in three clinical trials: FAST-1, FAST-2, and FAST-3.^{136,163,164} FAST-1 was a double-blind, placebo-controlled trial that demonstrated faster symptom relief (0.8 vs 16.9 hours) but no difference in the degree of symptom relief.^{4,163} The FAST-2 study demonstrated improved time to symptom relief in a double-blind study comparing icatibant to oral tranexamic acid (onset of symptom improvement 0.9 vs 7.8 hours).^{4,163} FAST-3 was a phase 3 double-blind, randomized, placebo-controlled trial that found a decrease in the time to primary symptom relief (2.0 vs 19.8 hours) and complete symptom relief (median 8.0 vs 36 hours).^{4,164} The literature suggests that the time to symptom improvement ranges from several minutes up to seven hours for icatibant. Of studies reporting improvement, approximately half of patients improve within 30 minutes, while time to complete symptom resolution ranges from 0.5-16 hours.^{136,165-174} Importantly, 40% of cases have complete resolution under four hours.^{136,165-173} A phase 2 multicenter, randomized controlled trial by Bas et al. evaluated icatibant vs steroids plus antihistamines, finding a shorter time to symptom relief with icatibant (2 hours vs 11.7 hours).¹⁷⁴ More patients receiving icatibant also demonstrated resolution of edema at four hours. However, there was no difference in the degree of patient-reported symptom relief.^{4,136}

A systematic review published in 2017 evaluating medication use in ACEi-mediated angioedema concluded icatibant possessed the highest level of evidence due to better study quality, while FFP has limited evidence demonstrating benefit and inconsistent dosing strategies for ACEi-mediated angioedema.¹³⁶ This systematic review incorporated case reports, case series, a prospective observational study, and one randomized controlled trial. However, the recommendations were limited by low quality evidence and significant heterogeneity with respect to the severity of angioedema and clinical outcomes.¹⁷⁵ Most of the included studies evaluated time to discharge and time to symptom relief, rather than the need for definitive airway, peak symptoms severity, duration of mechanical ventilation, and hospital/ICU admission.^{136,175} Publication bias was also severe, limiting conclusions. Studies following the publication of this systematic review from 2017 suggest no difference in time to discharge with icatibant.¹⁷⁵ Sinert et al. evaluated icatibant vs placebo in a phase III, double-blind clinical trial.¹⁷⁶ Time to discharge was four hours in both groups, with similar time of symptom relief.¹⁷⁶ A second prospective, randomized study published by Straka et al. compared icatibant and placebo, finding no difference in symptom severity or duration.¹⁷⁷

The current literature evaluating targeted therapy for bradykinin-mediated angioedema suffers from several limitations, including significant heterogeneity in patient selection, outcomes, comparators, dosing, and study design, as well as low numbers of included patients and high risk of bias.^{1,4,136,175} Medication efficacy is controversial with delayed onset of action, variable relief of symptoms, and limited availability depending on the institution.^{136,175} Rather than primarily focus on administering medications that may or may not improve symptoms in bradykinin-mediated forms of angioedema, EPs should focus on managing the patient's airway.^{1,4,175}

Disposition

Disposition is mainly determined by airway involvement. Several studies have sought to predict airway compromise in patients with acute angioedema.^{1-5,85,178} Ishoo et al. performed a retrospective study of 80 patients with 93 acute episodes of angioedema.⁸⁵ Wheezing, voice change, hoarseness, and stridor predicted the need for airway intervention. This study categorized patients based on the anatomic location of angioedema (Table 4).⁸⁵ A subsequent study published one

year later found the same factors predict need for definitive airway.¹⁷⁸ Importantly, these factors require further validation and laryngeal visualization for staging.

Patients with respiratory or airway distress require ICU admission, as well as those with stage III and IV edema due to risk of progression.^{1-5,7,8,89} Patients with stable or improving stage I or II edema of the face, lip, or soft palate should be monitored for several hours to evaluate for worsening of the angioedema.^{1-5,7,8,89,102} Patients with stage I angioedema can be discharged with follow-up after evaluation for progression. Patients with stage II angioedema are often discharged home within 24 hours, and ED observation units provide an optimal setting for monitoring of these patients.^{1,4} However, if edema involves ≥ 3 sites (lips, tongue, mouth floor, soft palate, and larynx), admission is recommended due to greater risk of airway involvement.⁸⁹

Patients with acute and recurrent angioedema may benefit from consultation with allergy/immunology specialists to discuss laboratory testing and arrange follow-up, particularly in patients with HAE.^{1-5,7,8,102} Patients with a first episode of angioedema, no response to anaphylaxis treatment, or family history of HAE require follow-up with an allergy/immunology specialist. These specialists can help diagnose a specific cause, evaluate and educate the patient concerning triggers, and provide prophylactic medications, which may prevent the need for ED care.^{1,4,179,180} Patients with known HAE and a recurrent attack may present with an action plan and recommended therapies, which should be followed when possible.^{102,181,182}

Patients discharged from the ED with histamine-mediated angioedema and those with unclear etiology or first-time episode should be prescribed epinephrine autoinjectors and educated on potential triggers.^{69,102} Family and friends should also be educated on these factors. Patients with respiratory distress or airway swelling after discharge should use the epinephrine autoinjector and immediately return to the ED. The patient with ACEi-mediated angioedema must discontinue his or her medication, and an alternative agent should be discussed with the patient's primary care provider.^{1-5,7,8,102} Most patients can use calcium channel blockers or angiotensin receptor blockers without developing a recurrence of their angioedema.^{1,183,184} The literature suggests the incidence of angioedema with ARB is 0.11%, which is not statistically different than placebo.¹⁸⁵

Table 4. Predicting airway compromise based on anatomic location of angioedema.⁸⁵

Stage	Site	Frequency	Discharge	Inpatient	ICU	Intervention
I	Face, lip	31%	48%	52%	0%	0%
II	Soft palate	5%	60%	40%	0%	0%
III	Tongue	32%	26%	7%	67%	7%
IV	Larynx	31%	0%	0%	100%	24%

ICU, intensive care unit.

CONCLUSION

Angioedema is non-dependent, non-pitting edema at a variety of sites. Its forms can be divided into histamine-mediated and bradykinin-mediated types. Histamine-mediated forms can present similarly to anaphylaxis, while bradykinin-mediated angioedema is slower in onset, presents with greater face and oropharyngeal involvement, and has higher risk of progression. Initial evaluation and management should focus on the airway, followed by an evaluation for family history, medications, and prior episodes. Histamine-mediated angioedema is treated like anaphylaxis with epinephrine, antihistamines, and steroids. These medications are not effective for the bradykinin-mediated forms, although they can be attempted in the absence of effective therapy. Other medications include C1-INH protein replacement, kallikrein inhibitor, and bradykinin receptor antagonists. Several studies have evaluated these for angioedema, but the evidence is lacking for efficacy. The focus should be on airway management rather than medications in bradykinin-mediated angioedema. This may require fiberoptic or video laryngoscopy, with preparation for cricothyrotomy. Disposition depends on patient's airway and respiratory status, as well as the involved sites.

Address for Correspondence: Brit Long, MD, Brooke Army Medical Center, Department of Emergency Medicine, 3841 Roger Brooke Dr., Fort Sam Houston, TX 78234. Email: brit.long@yahoo.com.

Conflicts of Interest: By the WestJEM article submission agreement, all authors are required to disclose all affiliations, funding sources and financial or management relationships that could be perceived as potential sources of bias. No author has professional or financial relationships with any companies that are relevant to this study. This review does not reflect the views or opinions of the U.S. government, Department of Defense, U.S. Army, U.S. Air Force, or SAUSHEC EM Residency Program. There are no conflicts of interest or sources of funding to declare.

Copyright: © 2019 Long et al. This is an open access article distributed in accordance with the terms of the Creative Commons Attribution (CC BY 4.0) License. See: <http://creativecommons.org/licenses/by/4.0/>

REFERENCES

- Moellman JJ, Bernstein JA, Lindsell C, et al. A consensus parameter for the evaluation and management of angioedema in the emergency department. *Acad Emerg Med.* 2014;21(4):469-84.
- Bork K. An evidence based therapeutic approach to hereditary and acquired angioedema. *Curr Opin Allergy Clin Immunol.* 2014;14(4):354-62.
- Bork K. Angioedema. *Immunol Allergy Clin North Am.* 2014;34(1):23-31.
- Wilkerson RG. Angioedema in the emergency department: an evidence-based review. *Emerg Med Pract.* 2012;14(11): 1-21.
- Frigas E, Nzeako UC. Angioedema. Pathogenesis, differential diagnosis, and treatment. *Clin Rev Allergy Immunol.* 2002;23(2):217-3.
- Kim SJ, Brooks JC, Sheikh J, et al. Angioedema deaths in the United States, 1979-2010. *Ann Allergy Asthma Immunol.* 2014;113(6):630-4.
- Bernstein JA, Moellman J. Emerging concepts in the diagnosis and treatment of patients with undifferentiated angioedema. *Int J Emerg Med.* 2012;5(1):39.
- Bernstein JA, Cremonesi P, Hoffman TK, et al. Angioedema in the emergency department: a practical guide to differential diagnosis and management. *Int J Emerg Med.* 2017;10(1):15.
- Gill P, Betschel SD. The clinical evaluation of angioedema. *Immunol Allergy Clin N Am.* 2017;37(3):449-66.
- Gaeta TJ, Clark S, Pelletier AJ, et al. National study of US emergency department visits for acute allergic reactions, 1993 to 2004. *Ann Allergy Asthma Immunol.* 2007;98(4):360-5.
- Zilberberg MD, Jacobsen T, Tillotson G. The burden of hospitalizations and emergency department visits with hereditary angioedema and angioedema in the United States, 2007. *Allergy Asthma Proc.* 2010;31(6):511-9.
- Lin RY, Anderson AS, Shah SN, et al. Increasing anaphylaxis hospitalizations in the first 2 decades of life: New York State, 1990-2006. *Ann Allergy Asthma Immunol.* 2008;101(4):387-93.
- Zuraw BL. Clinical practice. Hereditary angioedema. *N Engl J Med.* 2008;359(10):1027-36.
- Bas M, Adams V, Suvorava T, et al. Nonallergic angioedema: role of bradykinin. *Allergy.* 2007;62(8):842-56.
- Bernstein JA. Update on angioedema: evaluation, diagnosis, and treatment. *Allergy Asthma Proc.* 2011;32(6):408-12.
- Banerji A, Clark S, Blanda M, et al. Multicenter study of patients with angiotensin-converting enzyme inhibitor induced angioedema who present to the emergency department. *Ann Allergy Asthma Immunol.* 2008;100(4):327-32.
- Bork K, Hardt J, Witzke G. Fatal laryngeal attacks and mortality in hereditary angioedema due to C1-INH deficiency. *J Allergy Clin Immunol.* 2012;130(3):692-7.
- Bork K. Recurrent angioedema and the threat of asphyxiation. *Dtsch Arztebl Int.* 2010;107(23):408-14.
- Craig T, Pursun EA, Bork K, et al. WAO Guideline for the Management of Hereditary Angioedema. *World Allergy Organ J.* 2012;5(12):182-99.
- Hoyer C, Hill MR, Kaminski ER. Angio-oedema: an overview of differential diagnosis and clinical management. *Contin Educ Anaesth Crit Care Pain.* 2012;12(6):307-11.
- Bluestein HM, Hoover TA, Banerji AS, et al. Angiotensin-converting enzyme inhibitor-induced angioedema in a community hospital emergency department. *Ann Allergy Asthma Immunol.* 2009;103(6):502-7.
- Bernstein JA, Moellman JJ. Progress in the emergency management of hereditary angioedema: focus on new treatment options in the United States. *Postgrad Med.* 2012;124(3):91-100.
- Lang DM, Aberer W, Bernstein JA, et al. International consensus on hereditary and acquired angioedema. *Ann Allergy Asthma Immunol.* 2012;109(6):395-402.

24. Moellman JJ, Bernstein JA. Diagnosis and management of hereditary angioedema: an emergency medicine perspective. *J Emerg Med*. 2012;43(2):391-400.
25. Ghably J, Saleh H, Vyas H, et al. Paul Ehrlich's mastzellen: a historical perspective of relevant developments in mast cell biology. *Methods Mol Biol*. 2015;1220:3-10.
26. Krishnaswamy G, Ajitawi O, Chi DS. The human mast cell: an overview. *Methods Mol Biol*. 2006;315:13-34.
27. Krishnaswamy G, Kelley J, Johnson D, et al. The human mast cell: functions in physiology and disease. *Front Biosci*. 2001;6:D1109-27.
28. Grigoriadou S, Longhurst HJ. Clinical Immunology Review Series: an approach to the patient with angio-oedema. *Clin Exp Immunol*. 2008;155(3):367-77.
29. Abbas AK, Pober JS, Lichtman AH. (2010). Cellular and Molecular Immunology, 2nd ed. Philadelphia, Pennsylvania: Saunders/Elsevier.
30. Morgan BP. Hereditary angioedema-therapies old and new. *N Engl J Med*. 2010;363(6):581-3.
31. Saleh H, Embry S, Nauli A, et al. Anaphylactic reactions to oligosaccharides in red meat: a syndrome in evolution. *Clin Mol Allergy*. 2012;10(1):5.
32. Miller CW, Guha B, Krishnaswamy G. Exercise-induced anaphylaxis: a serious but preventable disorder. *Phys Sportsmed*. 2008;36(1):87-94.
33. Ismail S, Cheng L, Grigoriadou S, et al. Lesson of the month 2: the limitations of steroid therapy in bradykinin-mediated angioedema attacks. *Clin Med (Lond)*. 2015;15(1):101-3.
34. Lawlor F, Black AK, Breathnach AS, et al. Vibratory angioedema: lesion induction, clinical features, laboratory and ultrastructural findings and response to therapy. *Br J Dermatol*. 1989;120(1):93-9.
35. Rose RF, Bhushan M, King CM, et al. Solar angioedema: an uncommonly recognized condition? *Photodermatol Photoimmunol Photomed*. 2005;21(5):226-8.
36. Bentley B 2nd. Cold-induced urticaria and angioedema: diagnosis and management. *Am J Emerg Med*. 1993;11(1):43-6.
37. Cicardi M, Zingale L, Zanichelli A, et al. C1 inhibitor: molecular and clinical aspects. Springer Semin Immunopathol. 2005;27(3):286-98.
38. Maurer M, Bader M, Bas MB, et al. New topics in bradykinin research. *Allergy*. 2011;66(11):1397-406.
39. Kaplan AP, Joseph K. Complement, kinins, and hereditary angioedema: mechanisms of plasma instability when C1 inhibitor is absent. *Clin Rev Allergy Immunol*. 2016;51(2):207-15.
40. Kaplan AP, Joseph K. The bradykinin-forming cascade and its role in hereditary angioedema. *Ann Allergy Asthma Immunol*. 2010;104(3):193-204.
41. Kaplan AP, Joseph K. Pathogenesis of hereditary angioedema: the role of the bradykinin-forming cascade. *Immunol Allergy Clin North Am*. 2017;37(3):513-25.
42. Gompels MM, Lock RJ, Morgan JE, et al. A multicentre study of the diagnostic efficiency of serological investigations for C1 inhibitor deficiency. *J Clin Pathol*. 2002;55(2):145-7.
43. Tarzi MD, Hickey A, Forster T, et al. An evaluation of tests used for the diagnosis and monitoring of C1 inhibitor deficiency: normal serum C4 does not exclude hereditary angio-oedema. *Clin Exp Immunol*. 2007;149(3):513-6.
44. Gang C, Lindsell CJ, Moellman J, et al. Factors associated with hospitalization of patients with angiotensin-converting enzyme inhibitor-induced angioedema. *Allergy Asthma Proc*. 2013;34(3):267-73.
45. Holm JP, Ovesen T. Increasing rate of angiotensin-converting enzyme inhibitor-related upper airway angio-oedema. *Dan Med J*. 2012;59(6):A4449.
46. Williams-Johnson JA, Hemmings S, Williams EW, et al. Six years experience of angioedema at the University Hospital of the West Indies. *West Indian Med J*. 2007;56(3):278-81.
47. Brown NJ, Ray WA, Snowden M, et al. Black Americans have an increased rate of angiotensin converting enzyme inhibitor-associated angioedema. *Clin Pharmacol Ther*. 1996;60(1):8-13.
48. Wilkin JK, Hammond JJ, Kirkendall WM. The captopril-induced eruption. A possible mechanism: cutaneous kinin potentiation. *Arch Dermatol*. 1980;116(8):902-5.
49. Nussberger J, Cugno M, Amstutz C, et al. Plasma bradykinin in angio-oedema. *Lancet*. 1998;351(9117):1693-7.
50. Miller DR, Oliveria SA, Berlowitz DR, et al. Angioedema incidence in US veterans initiating angiotensin-converting enzyme inhibitors. *Hypertension*. 2008;51(6):1624-30.
51. Lin RY, Levine RJ, Lin H. Adverse drug effects and angioedema hospitalizations in the United States from 2000 to 2009. *Allergy Asthma Proc*. 2013;34(1):65-71.
52. Kostis JB, Kim HJ, Rusnak J, et al. Incidence and characteristics of angioedema associated with enalapril. *Arch Intern Med*. 2005;165(14):1637-42.
53. Byrd JB, Adam A, Brown NJ. Angiotensin-converting enzyme inhibitor-associated angioedema. *Immunol Allergy Clin North Am*. 2006;26(4):725-37.
54. Blanch A, Roche O, Urrutia I, et al. First case of homozygous C1 inhibitor deficiency. *J Allergy Clin Immunol*. 2006;118(6):1330-5.
55. Bork K, Meng G, Staubach P, et al. Hereditary angioedema: new findings concerning symptoms, affected organs, and course. *Am J Med*. 2006;119(3):267-74.
56. Berges-Gimeno MP, Martin-Lazaro J. Allergic reactions to nonsteroidal anti-inflammatory drugs: is newer better? *Curr Allergy Asthma Rep*. 2007;7(1):35-40.
57. Zuraw BL, Christiansen SC. Pathophysiology of hereditary angioedema. *Am J Rhinol Allergy*. 2011;25(6):373-8.
58. Frazer-Abel A, Giclas PC. Update on laboratory tests for the diagnosis and differentiation of hereditary angioedema and acquired angioedema. *Allergy Asthma Proc*. 2011;32(Suppl 1):S17-21.
59. Yamamoto T, Horiuchi T, Miyahara H, et al. Hereditary angioedema in Japan: genetic analysis of 13 unrelated cases. *Am J Med Sci*. 2012;343(3):210-4.
60. Warin RP, Cunliffe WJ, Greaves MW, et al. Recurrent angioedema: familial and oestrogen-induced. *Br J Dermatol*. 1986;115(6):731-4.
61. Bork K, Barnstedt SE, Koch P, et al. Hereditary angioedema with normal C1-inhibitor activity in women. *Lancet*. 2000;356(9225):213-7.
62. Binkley KE, Davis A 3rd. Clinical, biochemical, and genetic characterization of a novel estrogen-dependent inherited form of

- angioedema. *J Allergy Clin Immunol*. 2000;106(3):546-50.
63. Prematta MJ, Kemp JG, Gibbs JG, et al. Frequency, timing, and type of prodromal symptoms associated with hereditary angioedema attacks. *Allergy Asthma Proc*. 2009;30(5):506-11.
 64. Baeza ML, Rodriguez-Marco A, Prieto A, et al. Factor XII gene missense mutation Thr328Lys in an Arab family with hereditary angioedema type III. *Allergy*. 2011;66(7):981-2.
 65. Caldwell JR, Ruddy S, Schur PH, et al. Acquired C1 inhibitor deficiency in lymphosarcoma. *Clin Immunol Immunopathol*. 1972;1(1):39-52.
 66. Jackson J, Sim RB, Whelan A, et al. An IgG autoantibody which inactivates C1-inhibitor. *Nature*. 1986;323(6090):722-4.
 67. Chevailler A, Arlaud G, Ponard D, et al. C-1-inhibitor binding monoclonal immunoglobins in three patients with acquired angioneurotic edema. *J Allergy Clin Immunol*. 1996;97(4):998-1008.
 68. D'Incan M, Tridon A, Ponard D, et al. Acquired angioedema with C1 inhibitor deficiency: is the distinction between type I and type II still relevant? *Dermatology*. 1999;199(3):227-30.
 69. Busse PJ. Angioedema: differential diagnosis and treatment. *Allergy Asthma Proc*. 2011;32(Suppl 1):3-11.
 70. Cicardi M, Zingale LC, Pappalardo E, et al. Autoantibodies and lymphoproliferative diseases in acquired C1-inhibitor deficiencies. *Medicine (Baltimore)*. 2003;82(4):274-81.
 71. Fremeaux-Bacchi V, Guinnee MT, Cacoub P, et al. Prevalence of monoclonal gammopathy in patients presenting with acquired angioedema type 2. *Am J Med*. 2002;113(3):194-9.
 72. Bertazzoni G, Spina MT, Scarpellini MG, et al. Drug-induced angioedema: experience of Italian emergency departments. *Intern Emerg Med*. 2014;9(4):455-62.
 73. Toh S, Reichman ME, Houstoun M, et al. Comparative risk for angioedema associated with the use of drugs that target the renin-angiotensin-aldosterone system. *Arch Intern Med*. 2012;172(20):1582-9.
 74. Strom BL, Carson JL, Morse ML, et al. The effect of indication on hypersensitivity reactions associated with zomepirac sodium and other nonsteroidal antiinflammatory drugs. *Arthritis Rheum*. 1987;30(10):1142-8.
 75. Settipane GA. Aspirin and allergic diseases: a review. *Am J Med*. 1983;74(6A):102-9.
 76. Beavers CJ, Dunn SP, Macaulay TE. The role of angiotensin receptor blockers in patients with angiotensin-converting enzyme inhibitor-induced angioedema. *Ann Pharmacother*. 2011;45(4):520-4.
 77. Kidney Disease Outcomes Quality Initiative (K/DOQI). K/DOQI clinical practice guidelines on hypertension and antihypertensive agents in chronic kidney disease. *Am J Kidney Dis*. 2004;43(Suppl 1):S1-290.
 78. Bas M, Greve J, Strassen U, et al. Angioedema induced by cardiovascular drugs: new players join old friends. *Allergy*. 2015;70(10):1196-200.
 79. Bezalel S, Mahlab-Guri K, Asher I, et al. Angiotensin converting enzyme inhibitor-induced angioedema. *Am J Med*. 2015;128(2):120-5.
 80. Baş M, Hoffmann TK, Kojda G. Icatibant in ACE-inhibitor-induced angioedema. *N Engl J Med*. 2015;372(19):1867-8.
 81. Sala-Cunill A, Björkqvist J, Senter R, et al. Plasma contact system activation drives anaphylaxis in severe mast cell mediated allergic reactions. *J Allergy Clin Immunol*. 2015;135(4):1031-43.e6.
 82. US Hereditary Angioedema Association. Comprehensive angioedema typology and description. Available at: <http://www.haea.org/professionals/angioedema/>. Accessed November 3, 2015.
 83. Cicardi M, Aberer W, Banerji A, et al. Classification, diagnosis, and approach to treatment for angioedema: consensus report from the Hereditary Angioedema International Working Group. *Allergy*. 2014;69(5):602-16.
 84. Zingale LC, Beltrami L, Zanichelli A, et al. Angioedema without urticaria: a large clinical survey. *CMAJ*. 2006;175(9):1065-70.
 85. Ishoo E, Shah UK, Grillone GA, et al. Predicting airway risk in angioedema: staging system based on presentation. *Otolaryngol Head Neck Surg*. 1999;121(3):263-8.
 86. Agah R, Bandi V, Guntupalli KK. Angioedema: the role of ACE inhibitors and factors associated with poor clinical outcome. *Intensive Care Med*. 1997;23(7):793-6.
 87. Al-Khudari S, Loochtan MJ, Peterson E, et al. Management of angiotensin-converting enzyme inhibitor-induced angioedema. *Laryngoscope*. 2011;121(11):2327-34.
 88. Gannon TH, Eby TL. Angioedema from angiotensin converting enzyme inhibitors: a cause of upper airway obstruction. *Laryngoscope*. 1990;100(11):1156-60.
 89. McCormick M, Folbe AJ, Lin HS, et al. Site involvement as a predictor of airway intervention in angioedema. *Laryngoscope*. 2011;121(2):262-6.
 90. Pigman EC, Scott JL. Angioedema in the emergency department: the impact of angiotensin-converting enzyme inhibitors. *Am J Emerg Med*. 1993;11(4):350-4.
 91. Saxena S, Gierl B, Eibling DE. Supraglottic swelling may not correlate with tongue swelling in angiotensin converting enzyme inhibitor-induced angioedema. *Laryngoscope*. 2010;120(1):62-4.
 92. Stojiljkovic L. Renin-angiotensin system inhibitors and angioedema: anesthetic implications. *Curr Opin Anaesthesiol*. 2012;25(3):356-62.
 93. Bork K, Staubach P, Eckardt AJ, et al. Symptoms, course, and complications of abdominal attacks in hereditary angioedema due to C1 inhibitor deficiency. *Am J Gastroenterol*. 2006;101(3):619-27.
 94. Khan DA. Hereditary angioedema: Historical aspects, classification, pathophysiology, clinical presentation, and laboratory diagnosis. *Allergy Asthma Proc*. 2011;32(1):1-10.
 95. Champion RH, Roberts SO, Carpenter RG, et al. Urticaria and angioedema. A review of 554 patients. *Br J Dermatol*. 1969;81(8):588-97.
 96. Vazquez Nava F, Almeida Arvizu VM, Sanchez Nuncio HR, et al. [Prevalence and potential triggering factors of chronic urticaria and angioedema in an urban area of northeastern Mexico]. [Article in Spanish]. *Rev Alerg Mex*. 2004;51(5):181-8.
 97. Lenschow M, Bas M, Johnson F, et al. A score for the differential diagnosis of bradykinin- and histamine-induced head and neck swellings. *Eur Arch Otorhinolaryngol*. 2018;275(7):1767-73.
 98. Calbo L, Quattrocchi P, Ferlazzo B. Abdominal attack of hereditary angioedema associated with marked leucocytosis. A case report. *Ital J Gastroenterol*. 1992;24(8):464-5.
 99. Zuraw BL, Bernstein JA, Lang DM, et al. A focused parameter update: hereditary angioedema, acquired C1 inhibitor deficiency, and

- angiotensin-converting enzyme inhibitor-associated angioedema. *J Allergy Clin Immunol*. 2013;131(6):1491-3.
100. Markovic SN, Inwards DJ, Phylilly RP. Acquired C1 esterase inhibitor deficiency. *Ann Intern Med*. 2000;133(10):839.
 101. Li H, Busse P, Lumry WR, et al. Comparison of chromogenic and ELISA functional C1 inhibitor tests in diagnosing hereditary angioedema. *J Allergy Clin Immunol Pract*. 2015;3(2):200-5.
 102. Bowen T, Cicardi M, Farkas H, et al. 2010 International consensus algorithm for the diagnosis, therapy and management of hereditary angioedema. *Allergy Asthma Clin Immunol*. 2010;6(1):24.
 103. Alsenz, J, Bork K, Loos M. Autoantibody-mediated acquired deficiency of C1 inhibitor. *N Engl J Med*. 1987;316(22):1360-6.
 104. Scheirey CD, Scholz FJ, Shortsleeve MJ, et al. Angiotensin-converting enzyme inhibitor-induced small-bowel angioedema: clinical and imaging findings in 20 patients. *AJR Am J Roentgenol*. 2011;197(2):393-8.
 105. Jaiganesh T, Wiese M, Hollingsworth J, et al. Acute angioedema: recognition and management in the emergency department. *Eur J Emerg Med*. 2013;20(1):10-7.
 106. Sofia S, Casali A, Bolondi L. Sonographic findings in abdominal hereditary angioedema. *J Clin Ultrasound*. 1999;27(9):537-40.
 107. Walls R, Murphy M. (2012). *Manual of Emergency Airway Management*. Philadelphia, PA: Lippincott, Williams, and Wilkins, Wolters Kluwer.
 108. Kramer A, Müller D, Pfortner R, et al. Fiberoptic vs videolaryngoscopic (C-MAC®) D-BLADE) nasal awake intubation under local anaesthesia. *Anaesthesia*. 2015;70(4):400-6.
 109. Simmons ST, Schleich AR. Airway regional anesthesia for awake fiberoptic intubation. *Reg Anesth Pain Med*. 2002;27(2):180-92.
 110. Bramante RM, Rand M. Images in clinical medicine. Angioedema. *N Engl J Med*. 2011;365(2):e4.
 111. Richman MJ, Talan DA, Lumry WR. Treatment of laryngeal hereditary angioedema. *J Emerg Med*. 2012;42(1):44-7.
 112. James C, Bernstein JA. Current and future therapies for the treatment of histamine-induced angioedema. *Expert Opin Pharmacother*. 2017;18(3):253-62.
 113. Simons FE, Roberts JR, Gu X, et al. Epinephrine absorption in children with a history of anaphylaxis. *J Allergy Clin Immunol*. 1998;101(1 Pt 1):33-7.
 114. Simons FE, Gu X, Simons KJ. Epinephrine absorption in adults: intramuscular versus subcutaneous injection. *J Allergy Clin Immunol*. 2001;108(5):871-3.
 115. Johnston SL, Unsworth J, Gompels MM. Adrenaline given outside the context of life threatening allergic reactions. *BMJ*. 2003;326(7389):589-90.
 116. ECC Committee, Subcommittee and Task Forces of the American Heart Association. 2005 American Heart Association Guidelines for Cardiopulmonary Resuscitation and Emergency Cardiovascular Care. *Circulation*. 2005;112(24 Suppl):IV1-203.
 117. Runge JW, Martinez JC, Caravati EM, et al. Histamine antagonists in the treatment of acute allergic reactions. *Ann Emerg Med*. 1992;21(3):237-42.
 118. Lin RY, Curry A, Pesola GR, et al. Improved outcomes in patients with acute allergic syndromes who are treated with combined H1 and H2 antagonists. *Ann Emerg Med*. 2000;36(5):462-8.
 119. Breneman DL. Cetirizine versus hydroxyzine and placebo in chronic idiopathic urticaria. *Ann Pharmacother*. 1996;30(10):1075-9.
 120. Goh CL, Wong WK, Lim J. Cetirizine vs placebo in chronic idiopathic urticaria—a double-blind randomized cross-over study. *Ann Acad Med Singapore*. 1991;20(3):328-30.
 121. Finn AF Jr, Kaplan AP, Fretwell R, et al. A double-blind, placebo-controlled trial of fexofenadine HCl in the treatment of chronic idiopathic urticaria. *J Allergy Clin Immunol*. 1999;104(5):1071-8.
 122. Nelson HS, Reynolds R, Mason J. Fexofenadine HCl is safe and effective for treatment of chronic idiopathic urticaria. *Ann Allergy Asthma Immunol*. 2000;84(5):517-22.
 123. Kapp A, Wedi B. Chronic urticaria: clinical aspects and focus on a new antihistamine, levocetirizine. *J Drugs Dermatol*. 2004;3(6):632-9.
 124. Monroe EW, Bernstein DI, Fox RW, et al. Relative efficacy and safety of loratadine, hydroxyzine, and placebo in chronic idiopathic urticaria. *Arzneimittelforschung*. 1992;42(9):1119-21.
 125. Monroe EW. Relative efficacy and safety of loratidine, hydroxyzine, and placebo in chronic idiopathic urticaria and atopic dermatitis. *Clin Ther*. 1992;14(1):17-21.
 126. Handa S, Dogra S, Kumar B. Comparative efficacy of cetirizine and fexofenadine in the treatment of chronic idiopathic urticaria. *J Dermatolog Treat*. 2004;15(1):55-7.
 127. Kaplan AP. Clinical practice. Chronic urticaria and angioedema. *N Engl J Med*. 2002;346(3):175-9. Review.
 128. Sampson HA, Muñoz-Furlong A, Campbell RL, et al. Second symposium on the definition and management of anaphylaxis: summary report—second National Institute of Allergy and Infectious Disease/Food Allergy and Anaphylaxis Network symposium. *Ann Emerg Med*. 2006;47(4):373-80.
 129. Pickering RJ, Good RA, Kelly JR, et al. Replacement therapy in hereditary angioedema. Successful treatment of two patients with fresh frozen plasma. *Lancet*. 1969;1(7590):326-30.
 130. Hill BJ, Thomas SH, McCabe C. Fresh frozen plasma for acute exacerbations of hereditary angioedema. *Am J Emerg Med*. 2004;22(7):633.
 131. Pekdemir M, Ersel M, Aksay E, et al. Effective treatment of hereditary angioedema with fresh frozen plasma in an emergency department. *J Emerg Med*. 2007;33(2):137-9.
 132. Warriar MR, Copilevitz CA, Dykewicz MS, et al. Fresh frozen plasma in the treatment of resistant angiotensin-converting enzyme inhibitor angioedema. *Ann Allergy Asthma Immunol*. 2004;92(5):573-5.
 133. Bolton MR, Dooley-Hash SL. Angiotensin-converting enzyme inhibitor angioedema. *J Emerg Med*. 2012;43(4):e261-2.
 134. Prematta M, Gibbs JG, Pratt EL, et al. Fresh frozen plasma for the treatment of hereditary angioedema. *Ann Allergy Asthma Immunol*. 2007;98(4):383-8.
 135. Longhurst HJ. Emergency treatment of acute attacks in hereditary angioedema due to C1 inhibitor deficiency: what is the evidence? *Int J Clin Pract*. 2005;59(5):594-9.
 136. Riha HM, Summers BB, Rivera JV. Novel therapies for angiotensin-converting enzyme inhibitor-induced angioedema: a systematic review

- of current evidence. *J Emerg Med.* 2017;53(5):662-79.
137. Jaffe CJ, Atkinson JP, Gelfand JA, et al. Hereditary angioedema: the use of fresh frozen plasma for prophylaxis in patients undergoing oral surgery. *J Allergy Clin Immunol.* 1975;55(6):386-93.
 138. Saeb A, Hagglund KH, Cigolle CT. Using fresh frozen plasma for acute airway angioedema to prevent intubation in the emergency department: a retrospective cohort study. *Emerg Med Int.* 2016;2016:6091510.
 139. Hassen GW, Kalantari H, Parraga M, et al. Fresh frozen plasma for progressive and refractory angiotensin-converting enzyme inhibitor-induced angioedema. *J Emerg Med.* 2013;44(4):764-72.
 140. Karim MY, Masood A. Fresh-frozen plasma as a treatment for life threatening ACE-inhibitor angioedema. *J Allergy Clin Immunol.* 2002;109(2):370-1.
 141. Stewart M, McGlone R. Fresh frozen plasma in the treatment of ACE inhibitor induced angioedema. *BMJ Case Rep.* 2012;2012. pii: bcr2012006849.
 142. Lipski SM, Casimir G, Vanlommel M, et al. Angiotensin-converting enzyme inhibitors-induced angioedema treated by C1 esterase inhibitor concentrate (Berinert®): about one case and review of the therapeutic arsenal. *Clin Case Rep.* 2015;3(2):126-30.
 143. Tharayil AM, Chanda AH, Shiekh HA, et al. Life threatening angioedema in a patient on ACE inhibitor (ACEI) confined to the upper airway. *Qatar Med J.* 2014;2014(2):92-7.
 144. Shiber J. Lingual Angioedema due to ACE-Inhibitor. *Trop Med Surg.* 2014;2(1):161.
 145. Atalay E, Özdemir MT, Çiğsar G, et al. Angiotensin Converting Enzyme Inhibitor-related Angioedema: A Case of an Unexpected Death. *Iran J Allergy Asthma Immunol.* 2015;14(6):642-5.
 146. Millot I, Plancade D, Hosotte M, et al. Treatment of a life-threatening laryngeal bradykinin angio-oedema precipitated by dipeptidylpeptidase-4 inhibitor and angiotensin-I converting enzyme inhibitor with prothrombin complex concentrates. *Br J Anaesth.* 2012;109(5):827-9.
 147. Henry Li H, Riedl M, Kashkin J. Update on the use of C1-esterase inhibitor replacement therapy in the acute and prophylactic treatment of hereditary angioedema. *Clin Rev Allergy Immunol.* 2019;56(2):207-18.
 148. Brackertz D, Kueppers F. Hereditary angioneurotic oedema. *Lancet.* 1973;2(7830):680.
 149. Bork K, Barnstedt SE. Treatment of 193 episodes of laryngeal edema with C1 inhibitor concentrate in patients with hereditary angioedema. *Arch Intern Med.* 2001;161(5):714-8.
 150. Craig TJ, Levy RJ, Wasserman RL, et al. Efficacy of human C1 esterase inhibitor concentrate compared with placebo in acute hereditary angioedema attacks. *J Allergy Clin Immunol.* 2009;124(4):801-8.
 151. Craig TJ, Bewtra AK, Bahna SL, et al. C1 esterase inhibitor concentrate in 1085 hereditary angioedema attacks—final results of the I.M.P.A.C.T.2 study. *Allergy.* 2011;66(12):1604-11.
 152. Zuraw BL, Busse PJ, White M, et al. Nanofiltered C1 Inhibitor concentrate for treatment of hereditary angioedema. *N Engl J Med.* 2010;363(6):513-22.
 153. Riedl MA, Hurewitz DS, Levy R, et al. Nanofiltered C1 esterase inhibitor (human) for the treatment of acute attacks of hereditary angioedema: an open-label trial. *Ann Allergy Asthma Immunol.* 2012;108(1):49-53.
 154. Choi G, Soeters MR, Farkas H, et al. Recombinant human C1-inhibitor in the treatment of acute angioedema attacks. *Transfusion.* 2007;47(6):1028-32.
 155. Zuraw B, Cicardi M, Levy RJ, et al. Recombinant human C1-inhibitor for the treatment of acute angioedema attacks in patients with hereditary angioedema. *J Allergy Clin Immunol.* 2010;126(4):821-7.
 156. Riedl MA, Bernstein JA, Li H, et al. Recombinant human C1-esterase inhibitor relieves symptoms of hereditary angioedema attacks: phase 3, randomized, placebo-controlled trial. *Ann Allergy Asthma Immunol.* 2014;112(2):163-9.e1.
 157. Schneider L, Lumry W, Vegh A, et al. Critical role of kallikrein in hereditary angioedema pathogenesis: a clinical trial of ecallantide, a novel kallikrein inhibitor. *J Allergy Clin Immunol.* 2007;120(2):416-22.
 158. Lumry W, Li H, Schneider L, et al. Results of a repeat-dosing study of intravenous and subcutaneous administration of ecallantide (DX-88), a recombinant plasma kallikrein inhibitor, in patients with hereditary angioedema. *Ann Allergy Asthma Immunol.* 2007;98(Suppl 1):A29.
 159. Levy R, McNeil D, Li H, et al. Results of a 2-stage, phase 3 pivotal trial, EDEMA3: a study of subcutaneous DX-88 (ecallantide), a plasma kallikrein inhibitor, in patients with hereditary angioedema (HAE). *J Allergy Clin Immunol.* 2008;121(2 Suppl 1):S231.
 160. Levy RJ, Lumry WR, McNeil DL, et al. EDEMA4: a phase 3, double-blind study of subcutaneous ecallantide treatment for acute attacks of hereditary angioedema. *Ann Allergy Asthma Immunol.* 2010;104(6):523-9.
 161. Bernstein JA, Moellman JJ, Collins SP, et al. Effectiveness of ecallantide in treating angiotensin-converting enzyme inhibitor-induced angioedema in the emergency department. *Ann Allergy Asthma Immunol.* 2015;114(3):245-9.
 162. Lewis LM, Graffeo C, Crosley P, et al. Ecallantide for the acute treatment of angiotensin-converting enzyme inhibitor-induced angioedema: a multicenter, randomized, controlled trial. *Ann Emerg Med.* 2015;65(2):204-13.
 163. Cicardi M, Banerji A, Bracho F, et al. Icatibant, a new bradykinin receptor antagonist, in hereditary angioedema. *N Engl J Med.* 2010;363(6):532-41.
 164. Lumry WR, Li HH, Levy RJ, et al. Results from FAST-3: A Phase III Randomized, Double-Blind, Placebo-Controlled, Multicenter Study of Subcutaneous Icatibant in Patients with Acute Hereditary Angioedema (HAE) Attacks. *J Allergy Clin Immunol.* 2011;127(2 Suppl):AB1.
 165. Bartal C, Zeldetz V, Stavi V, et al. The role of icatibant—the B2 bradykinin receptor antagonist—in life-threatening laryngeal angioedema in the ED. *Am J Emerg Med.* 2015;33(3):479.e1-3.
 166. Charmillon A, Deibener J, Kaminsky P, et al. Angioedema induced by angiotensin converting enzyme inhibitors, potentiated by m-TOR inhibitors: successful treatment with icatibant. *Intensive Care Med.* 2014;40(6):893-4.
 167. Crooks NH, Patel J, Diwakar L, et al. Icatibant in the treatment of angiotensin-converting enzyme inhibitor-induced angioedema. *Case Rep Crit Care.* 2014;2014:864815.
 168. Gallitelli M, Alzetta M. Icatibant: a novel approach to the treatment of angioedema related to the use of angiotensin-converting enzyme

- inhibitors. *Am J Emerg Med.* 2012;30(8):1664.e1-2.
169. Mahajan H, Thynne T, Gabb GM, et al. Drug safety in Aboriginal Australians: three cases of angiotensin-converting enzyme inhibitor angioedema. *Intern Med J.* 2015;45(2):231-3.
170. Bas M, Greve J, Stelter K, et al. Therapeutic efficacy of icatibant in angioedema induced by angiotensin converting enzyme inhibitors: a case series. *Ann Emerg Med.* 2010;56(3):278-82.
171. Bova M, Guilarte M, Sala-Cunill A, et al. Treatment of ACEI-related angioedema with icatibant: a case series. *Intern Emerg Med.* 2015;10(3):345-50.
172. Jacob J, Bardes I, Palom X, et al. Angiotensin converting enzyme inhibitor-induced angioedema and icatibant: a new hope. *Intern Med J.* 2015;45(10):1093-4.
173. Volans A, Ferguson R. Using a bradykinin blocker in ACE inhibitor associated angioedema in the emergency department. *BMJ Case Rep.* 2013;2013. Pii:bcr2012008295.
174. Bas M, Greve J, Stelter K, et al. A randomized trial of icatibant in ACE-inhibitor-induced angioedema. *N Engl J Med.* 2015;372(5):418-25.
175. Wilkerson RG, Martinelli AN, Oliver WD. Treatment of angioedema induced by angiotensin-converting enzyme inhibitor. *J Emerg Med.* 2018;55(1):132-3.
176. Sinert R, Levy P, Bernstein JA, et al. Randomized trial of icatibant for angiotensin-converting enzyme inhibitor-induced upper airway angioedema. *J Allergy Clin Immunol Pract.* 2017;5(5):1402-9.e3.
177. Straka BT, Ramirez CE, Byrd JB, et al. Effect of bradykinin receptor antagonism on ACE inhibitor-associated angioedema. *J Allergy Clin Immunol.* 2017;140(1):242-8.
178. Bentsianov BL, Parhiscar A, Azer M, et al. The role of fiberoptic nasopharyngoscopy in the management of the acute airway in angioneurotic edema. *Laryngoscope.* 2000;110(12):2016-9.
179. Kreuz W, Rusicke E, Martinez-Saguer I, et al. Home therapy with intravenous human C1-inhibitor in children and adolescents with hereditary angioedema. *Transfusion.* 2012;52(1):100-7.
180. Cicardi M, Bork K, Caballero T, et al. Evidence based recommendations for the therapeutic management of angioedema owing to hereditary C1 inhibitor deficiency: consensus report of an International Working Group. *Allergy.* 2012;67(2):147-57.
181. Wahn V, Aberer W, Eberl W, et al. Hereditary angioedema (HAE) in children and adolescents—a consensus on therapeutic strategies. *Eur J Pediatr.* 2012;171(9):1339-48.
182. Epstein TG, Bernstein JA. Current and emerging management options for hereditary angioedema in the US. *Drugs.* 2008;68(18):2561-73.
183. Cicardi M, Zingale LC, Bergamaschini L, et al. Angioedema associated with angiotensin-converting enzyme inhibitor use: outcome after switching to a different treatment. *Arch Intern Med.* 2004;164(8):910-3.
184. Haymore BR, Yoon J, Mikita CP, et al. Risk of angioedema with angiotensin receptor blockers in patients with prior angioedema associated with angiotensin-converting enzyme inhibitors: a meta-analysis. *Ann Allergy Asthma Immunol.* 2008;101(5):495-9.
185. Makani H, Messerli FH, Romero J, et al. Meta-analysis of randomized trials of angioedema as an adverse event of renin-angiotensin system inhibitors. *Am J Cardiol.* 2012;110(3):383-91.