

## **UC Irvine**

### **Western Journal of Emergency Medicine: Integrating Emergency Care with Population Health**

#### **Title**

Intrapericardial Diaphragmatic Hernia

#### **Permalink**

<https://escholarship.org/uc/item/9h45w67f>

#### **Journal**

Western Journal of Emergency Medicine: Integrating Emergency Care with Population Health, 11(5)

#### **ISSN**

1936-900X

#### **Authors**

Heiner, Jason D  
Harper, Hillary M  
McArthur, Todd J

#### **Publication Date**

2010

#### **Copyright Information**

Copyright 2010 by the author(s). This work is made available under the terms of a Creative Commons Attribution-NonCommercial License, available at <https://creativecommons.org/licenses/by-nc/4.0/>

Peer reviewed

## Intrapericardial Diaphragmatic Hernia

Jason D. Heiner, MD  
Hillary M. Harper, MD  
Todd J. McArthur, MD

Madigan Army Medical Center, Department of Emergency Medicine, Tacoma, WA

*Supervising Section Editor:* Sean Henderson, MD

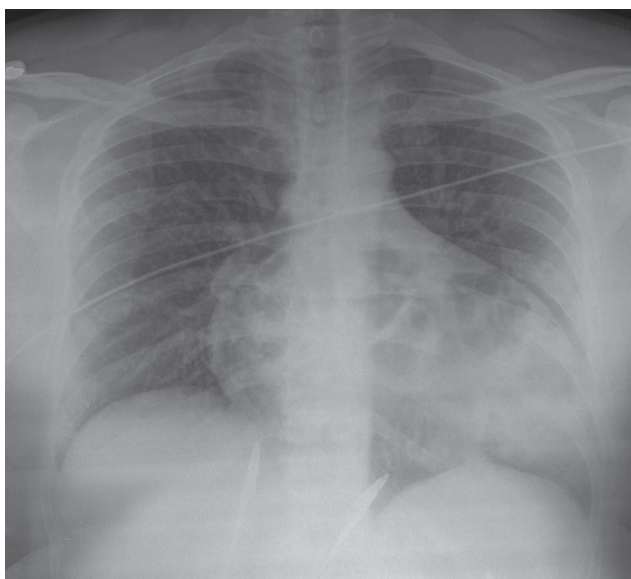
Submission history: Submitted July 3, 2010; Accepted July 16, 2010

Reprints available through open access at [http://escholarship.org/uc/uciem\\_westjem](http://escholarship.org/uc/uciem_westjem)

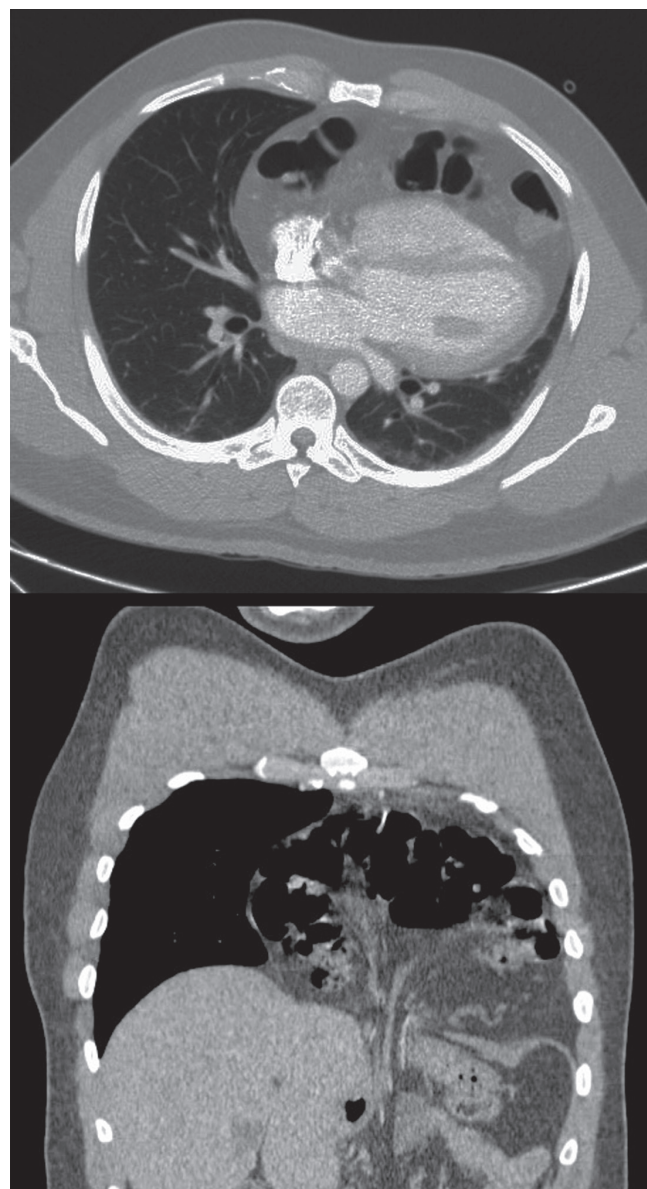
[West J Emerg Med. 2010;11(5):532-533.]

An adult male presented to the emergency department complaining of two days of exertional shortness of breath and progressive chest pain. He was afebrile with a blood pressure of 135/88 mmHg, heart rate of 105 beats/minute, respiratory rate of 22 breaths/minute, and a SaO<sub>2</sub> of 94% on room air. There was no history of preceding trauma, surgery or known congenital defects. A chest radiograph demonstrated an enlarged cardiac silhouette (Figure 1). Computed tomography revealed the presence of herniated visceral contents within the pericardial sac (Figure 2). Surgery was consulted for operative repair of this intrapericardial diaphragmatic hernia (IPDH), which was causing his presenting symptoms.

IPDH can occur from a traumatic or congenital diaphragmatic defect of the central tendon. It is a rare complication of diaphragmatic rupture, occurring in less than 1% of cases.<sup>1,2</sup> Blunt trauma resulting from automobile collisions has emerged as the most common primary identified cause.<sup>3</sup> The mechanism in blunt abdominal trauma involves



**Figure 1.** Chest radiograph demonstrating abnormal air shadowing over the enlarged pericardial sac.



**Figure 2.** Transverse (top) and sagittal (bottom) computed tomography (CT) images demonstrating posterior displacement of the anterior heart by transdiaphragmatic herniated bowel.

a sudden rise in intra-abdominal pressure, leading to rupture along the right or left side of the diaphragm extending into the pericardium. The organ most frequently involved in traumatic IPDH appears to be the transverse colon, followed by the stomach and the greater omentum.<sup>2</sup> Symptoms of IPDH are often nonspecific cardiorespiratory and gastrointestinal complaints. Patients range from being asymptomatic to having potentially fatal cardiac tamponade. The time interval from the presumed origin of the IPDH to the time of diagnosis is quite variable for both traumatic and congenital etiologies.<sup>1</sup> Treatment for IPDH is surgical. A thoracic approach is recommended by most authors in cases of delayed IPDH, as this allows for easier removal of pericardial adhesions; whereas, a trans-abdominal approach is preferred for surgical closure in acute presentations to provide good access to the tear in the diaphragm.<sup>3</sup>

---

*Address for Correspondence:* Jason Heiner, MD, Department of Emergency Medicine, Madigan Army Medical Center Tacoma, WA 98431.

---

*Conflicts of Interest:* By the WestJEM article submission agreement, all authors are required to disclose all affiliations, funding sources and financial or management relationships that could be perceived as potential sources of bias. The authors disclosed none.

The views expressed herein are solely those of the authors and do not represent the official views of the Department of Defense or Army Medical Department.

#### REFERENCES

1. Barrett J, Satz W. Traumatic, Pericardio-diaphragmatic rupture: an extremely rare cause of pericarditis. *J Emerg Med.* 2006; 30:141-5.
2. Reina A, Vidaña E, Soriano P, et al. Traumatic intrapericardial diaphragmatic hernia: case report and literature review. *Injury.* 2001; 32:153-6.
3. Sharma OP. Pericardio-diaphragmatic rupture: five new cases and literature review. *J Emerg Med.* 1999; 17:963-8.