

UC Davis

Dermatology Online Journal

Title

Primary milia localized to the vulva

Permalink

<https://escholarship.org/uc/item/13v166wf>

Journal

Dermatology Online Journal, 20(4)

Authors

Adotama, Prince
Susa, Joseph
Glass II, Donald A

Publication Date

2014

DOI

10.5070/D3204022339

Copyright Information

Copyright 2014 by the author(s). This work is made available under the terms of a Creative Commons Attribution-NonCommercial-NoDerivatives License, available at <https://creativecommons.org/licenses/by-nc-nd/4.0/>

Peer reviewed

Photo Vignette

Primary milia localized to the vulva

Prince Adotama BS¹, Joseph Susa DO², Donald A. Glass II MD PhD³

Dermatology Online Journal 20 (4): 15

¹Medical Student, UT Southwestern School of Medicine; ²Clinical Assistant Professor of Dermatology, UT Southwestern Medical Center; ³Assistant Professor of Dermatology, UT Southwestern Medical Center.

Correspondence:

Donald A. Glass II, M.D., Ph.D.
Department of Dermatology, University of Texas Southwestern Medical Center
5323 Harry Hines Blvd, Dallas, TX 75390-9069
214-633-1844 office 214-648-5559 fax
donald.glass@utsouthwestern.edu

Abstract

Multiple primary milia were found on the vulva of a 52-year-old woman who was referred to the dermatology clinic by her gynecologist. These lesions are commonly distributed on the face and rarely occur in this location without antecedent trauma. This report demonstrates the unique presentation of primary milia in the genital region and explores the diagnostic features and treatment methods of these lesions.

Introduction

Milia are benign superficial keratinous cysts that arise from pilosebaceous follicles. Primary milia arise spontaneously whereas secondary milia occur subsequent to an injury to the skin. These lesions are most commonly found on the cheeks and the eyelids [1]. We would like to describe a case of milia localized only to the vulva.

Case Synopsis

A 52-year-old woman was referred by her gynecologist to our dermatology clinic with a chief complaint of bumpy rough papules in the vulvar area for three years. These papules were neither pruritic nor painful, but had a negative impact on her quality of life. They were both cosmetically displeasing and caused her a great deal of emotional distress. She denied the use of occlusive undergarments or depilatories. She had no history of waxing or any other form of antecedent trauma. Her review of systems was unremarkable, and her past medical history was significant only for anxiety with a history of panic attacks.

On physical exam, the patient exhibited multiple grayish-white, spherical papules on the labia majora and minora that measured less than 1 cm each (Figure 1). She also had seborrheic keratoses and stucco keratoses on her torso and lower extremities, respectively.

A punch biopsy of one of the lesions from the vulva revealed small cysts in the dermis, lined by stratified squamous epithelium and filled with keratinaceous debris (Figure 2). These findings were consistent with milia.



Figure 1. Multiple grayish-white papules on the vulva

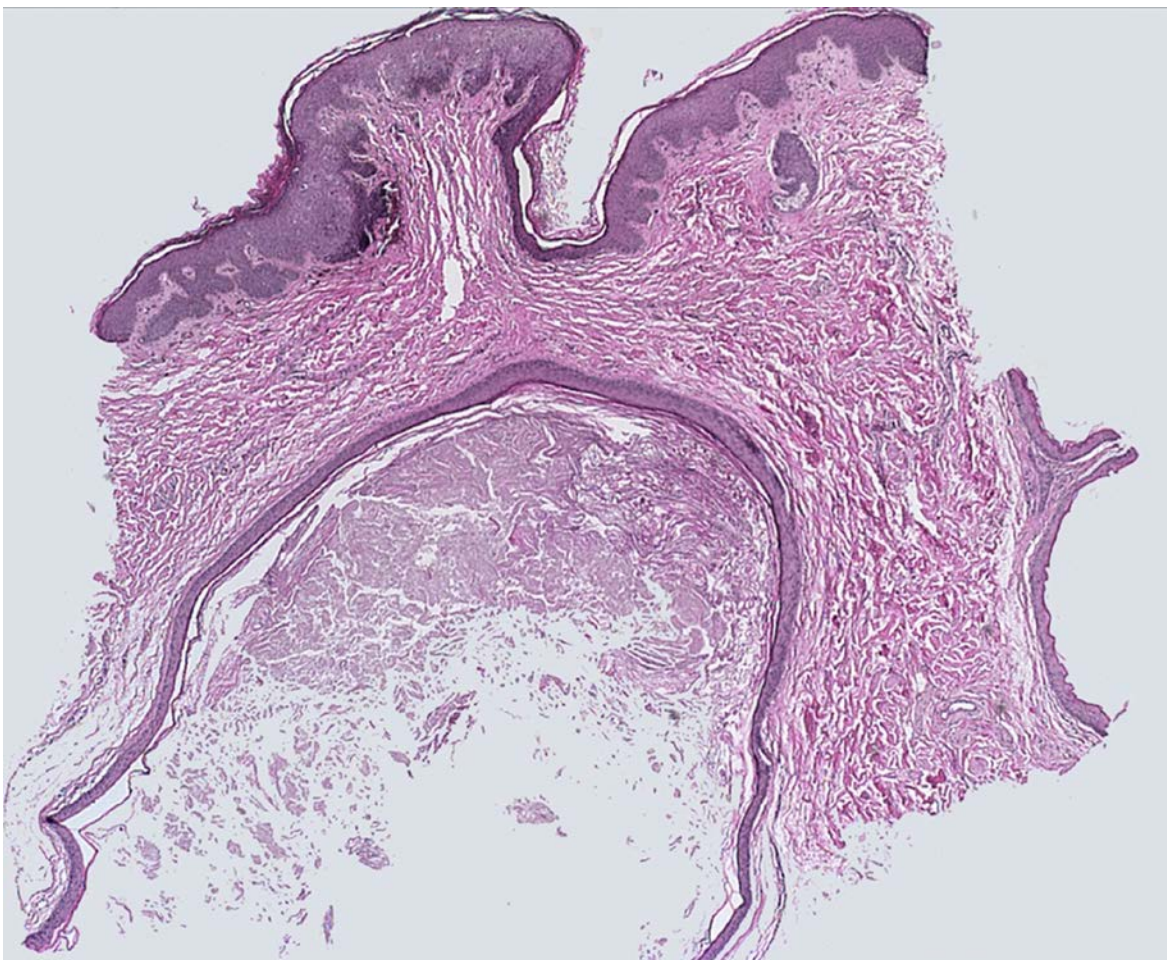


Figure 2. H&E staining of biopsy specimen from the patient revealing small cysts lined by stratified squamous epithelium and filled with keratinaceous debris. 40X magnification.

Discussion

Although the diagnosis of milia is not uncommon, the location of the lesions in this case is extremely rare. There have been two other cases of milia involving female genitalia [2] and one other case involving the penile shaft in the literature, all of which occurred in East Asians. To our knowledge, this is the only case of milia found on the vulva in someone of Caucasian ancestry. It is possible that this condition is under-reported, being benign, and that the incidence may be higher than the literature would suggest. External stimuli such as friction or rubbing might cause the invagination of epidermal cells, leading to the development of milia [3]. However, our patient denies any friction or rubbing of the area, suggesting that her milia are primary in nature.

Genital lesions can present a significant diagnostic dilemma to physicians and a great deal of anxiety to patients [4]. The differential diagnoses for genital lesions include molluscum contagiosum, lichen nitidus, steatocystoma multiplex, and calcinosis cutis [5]. Fortunately for our patient, milia are benign lesions and oftentimes clear spontaneously without the need for medical intervention. There are a variety of treatment options available for milia. Oral and topical retinoids are common choices and have had successful results. Treatment with both retinoids and minocycline has been reported [6]. Our patient is currently undergoing a trial of minocycline and topical tretinoin, and if this fails, surgical treatments such as curettage, incision, electrodesiccation, or extraction may be entertained.

References

1. Kanekura T, Kanda A, Higo A, Kanzaki T. Multiple milia localized to the vulva. *J Dermatol*. 1996;23(6):427-8. [PMID: 8708158]
2. Lim JH, Kim HO, Choi SW. A case of multiple milia occurring on the vulva. *Korean J Dermatol* 2001; 39: 607– 609.
3. Cho E, Cho SH, Lee JD. Idiopathic Multiple Eruptive Milia Occurred in Unusual Sites *Ann Dermatol*. 2010;22(4):465-67. [PMID: 21165223]
4. Weiss JN, Plumb RT. Benign lesions of the external genitalia. *Urol Clin North Am*. 1992;19(1):123-30. [PMID: 1736471]
5. Park JS, Lee MJ, Ko DK, Chung H, Park JS. Multiple primary milia on the penile shaft. *Int J Dermatol*. 2012 Nov;51(11):1388-9. [PMID: 23067092]
6. Batra P, Tsou HC, Warvcha M, Votava HJ, Stein J. Multiple eruptive milia. *Dermatol Online J*. 2009;15(8):20 [PMID: 19891928]