UC Irvine
Journal of Education and Teaching in Emergency Medicine

Title
A Case Report of Corneoscleral Laceration with Open Globe Injury and Iris Prolapse

Permalink
https://escholarship.org/uc/item/152844qp

Journal
Journal of Education and Teaching in Emergency Medicine, 11(2)

Authors
Frazier, Eric
Sauer, Adam
Lewis, Kristin

Publication Date
2026-04-30

DOI
10.5070/M5.52326

Copyright Information
This work is made available under the terms of a Creative Commons Attribution License, available at https://creativecommons.org/licenses/by/4.0/

Peer reviewed

eScholarship.org Powered by the California Digital Library
University of California

VISUALem

A Case Report of Corneoscleral Laceration with Open Globe Injury and Iris Prolapse

Eric Frazier, BS*, Adam Sauer, MD^ and Kristin Lewis, MD, MA^

*University of California, Irvine, School of Medicine, Irvine, CA

^University of California, Irvine, Department of Emergency Medicine, Orange, CA

Correspondence should be addressed to Kristin Lewis, MD, MA at klewis6@hs.uci.edu

Submitted: June 9, 2025; Accepted: March 16, 2026; Electronically Published: April 30, 2026; https://jetem.org/iris-prolapse/

Copyright: © 2026 Frazier, et al. This is an open access article distributed in accordance with the terms of the Creative Commons Attribution (CC BY 4.0) License. See: http://creativecommons.org/licenses/by/4.0/

ABSTRACT:

Open globe injury is defined as a full-thickness injury through all anatomical layers of the eye. Prolapse or herniation of the iris may be observed at presentation of an open globe injury, and iris prolapse is not well represented in the literature. This case report details the case of a 48-year-old male presenting with three hours of right eye pain after sustaining a traumatic injury due to a foreign body. Examination of the right eye revealed a 2 mm x 1 mm laceration to the 4-5 o'clock position with iris prolapse and plugging. The affected eye also revealed a teardrop-pupil with associated corectopia in the inferonasal direction and a 2 mm hyphema. The patient was diagnosed with a globe rupture and underwent same-day surgical intervention. This report emphasizes the use of fluorescein eye exams and explains the rationale against the measurement of intraocular pressures or removal of an obvious foreign body. The care provided represents strict adherence to the principles of management in ocular trauma and a positive outcome in which a patient's vision and visual acuity were relatively maintained.

Topics: Ophthalmologic trauma, open globe injury, globe rupture, iris prolapse, corneoscleral laceration.

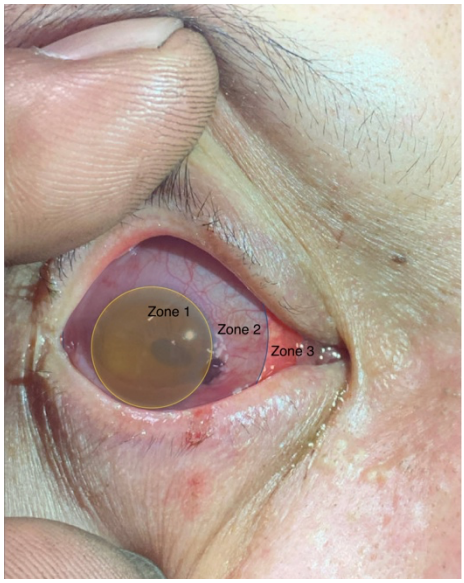

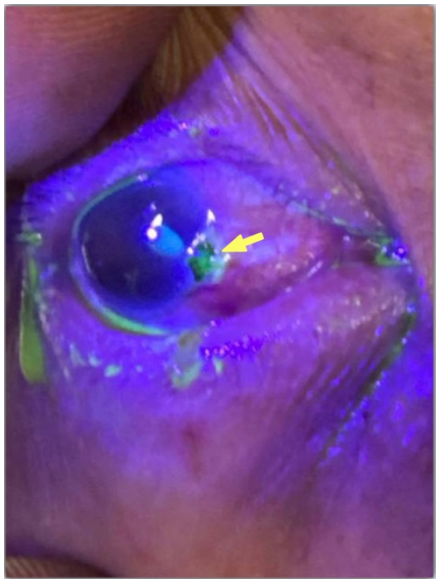

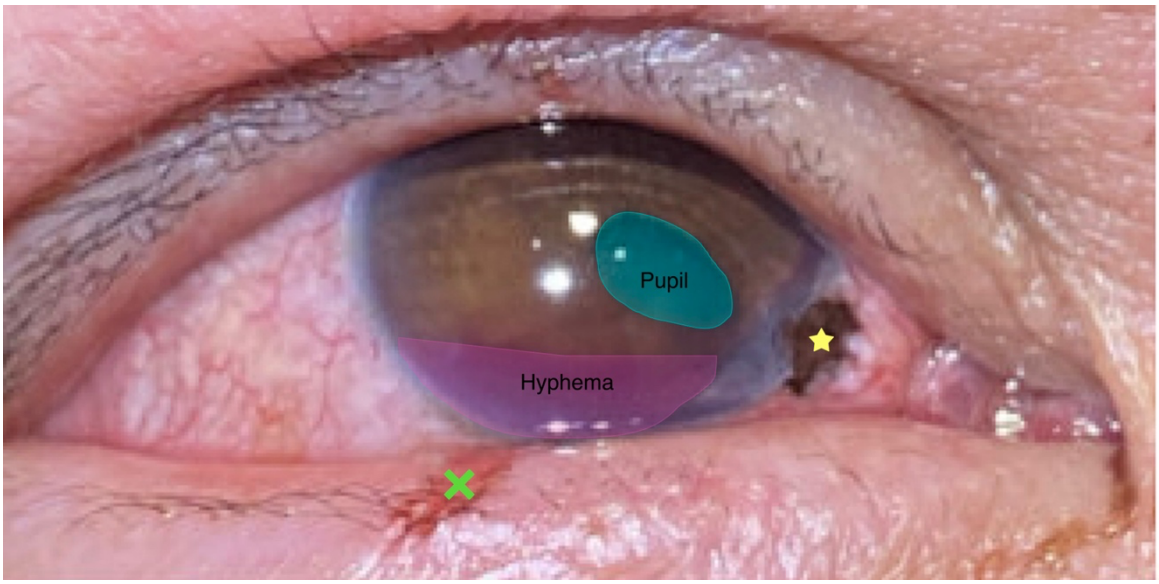

Brief introduction:
Ocular trauma is a relatively common reason for presentation to the emergency department (ED), representing a third of all ocular complaints and 3% of all presenting complaints to the ED.[1,2] The most common mechanism of injury is accidental entry of a foreign body into the eye, accounting for 29.8% of all mechanisms for ocular trauma.[2] These injuries are high risk, and can lead to partial or full loss of vision. Ocular trauma is the leading cause of acquired monocular vision loss in the United States.[1]

This case report aims to detail the clinical course and emergency department management of a middle-age male patient presenting with an ocular traumatic injury. This report identifies key clinical findings that support the diagnosis of an open globe injury (OGI) and contributes to the literature on a less common physical exam finding in the presentation of OGI. This case also emphasizes the importance of rapid identification, management, and intervention of ocular trauma to optimize patient outcomes. Written consent for the publication of this case report and the associated images was obtained.

Presenting concerns and clinical findings:
A 48-year-old male who is otherwise previously healthy presented with three hours of right ocular pain and suspected foreign body. The patient complained of a foreign body sensation and mild blurred vision with epiphora of the right eye. The patient reported walking past a coworker grinding metal and felt something strike his eye. Prior to seeking care in our emergency department, the patient had first gone to an outside hospital where he received a tetanus, diphtheria, acellular pertussis (Tdap) vaccine, but left against medical advice due to extended wait times for a transfer to a comprehensive ophthalmic care center. The patient denied any past medical history including glasses or contact use, and social history was only notable for employment as a truck driver. At presentation, the patient was afebrile and vital signs were unremarkable. On physical exam, extraocular movements were intact, there was conjunctival injection of the right eye, and the visual acuity was 20/50 uncorrected in the right eye and 20/30 uncorrected in the left eye. In the right eye, there was a corneoscleral laceration with a possible embedded foreign body, an irregularly shaped pupil, and a hyphema. The remainder of the physical exam was normal.

Significant findings:
Closer examination of the right eye revealed a 2 mm x 1 mm corneoscleral laceration to the 4-5 o'clock position at the border of zone I (yellow highlighting) and II (blue highlighting) with iris prolapse (yellow star) and plugging. Additionally, the affected eye revealed a peaked pupil (cyan highlighting) in the inferonasal direction with associated corectopia and a 2 mm Grade I hyphema (pink highlighting). Immediately inferior to the corneal laceration, 1 mm epithelial injury of the lower palpebra was present (green cross). Fluorescein exam demonstrated uptake at the 4-5 o'clock position (yellow arrow) but was negative for Seidel's sign.

Patient course:
Ophthalmology was consulted immediately, the patient was admitted to the hospital and started on IV vancomycin and ceftazidime, and further workup was obtained. Notably, intraocular pressures (IOP) were not measured. A non-contrast computed tomography scan of the orbits was obtained which did not identify any acute orbital findings or radiographic foreign bodies. Ophthalmology recommended surgical management of the injury, and the patient underwent emergent surgical correction the same day. Preoperatively vision was rechecked and confirmed to have worsened to 20/400, likely due to the worsening hyphema. The patient underwent surgical exploration, anterior chamber washout, and laceration repair without complication. Outpatient follow-up was scheduled on post-operative days zero and four. On post-operative day zero, visual acuity was 20/40 in the affected eye. Orbital ultrasonography was negative for retinal detachment, retinal tears, or intraocular foreign bodies. Fundal images obtained by ophthalmology demonstrated tractional vitreous hemorrhage inferonasally in the affected eye; however, image quality was limited by anterior chamber heme. By post-operative day four, the patient continued to report improvements and visual acuity was noted to be 20/60 in the affected eye.

Discussion:
Clinicians should maintain a broad differential in the initial evaluation of any ocular trauma including intraocular foreign body, hyphema, retinal detachment, vitreous hemorrhage, lens dislocation, corneal abrasion, and orbital fractures. Open globe injury is an essential consideration in the differential diagnosis of any ocular trauma. Globe rupture or OGI is defined as a full thickness injury to all layers of the eye.[3] Resultant prolapse or herniation of the iris is a potential complication of traumatic globe rupture; however, iris prolapse is underrepresented in the literature, and delineating what constitutes uveal or iris prolapse is unclear given that the uvea includes the iris. In this case report, we make the distinction that the patient demonstrated a traumatic prolapse of the iris because the color and texture of the tissue protruding from the site of injury matched that of the iris. Had the tissue appeared different in color or texture from the iris, the diagnosis of uveal prolapse would have been more appropriate because this diagnosis more broadly refers to a prolapse of any components of the uvea. The reported incidence of uveal prolapse varies greatly in the literature. Reports indicate that uveal prolapse may occur in 18.4% to 68.5% of traumatic OGIs, whereas iris prolapse, more specifically, may be present in just 34.5% of cases.[4-6] The limited literature and varying data on the incidence of iris prolapse stresses the importance of documenting less common presentations and the management of cases with positive patient outcomes.

In the initial evaluation of any ocular trauma, a mnemonic previously described by Kroesen et al can be useful in an approach to management.[7] After assessing the ABCs of Airway, Breathing, and Circulation, clinicians can use the ABCs of ocular trauma:
A = Acuity: obtain baseline visual acuity.
B = Best exam: an exam starting with the uninjured eye.
C = Contiguous structures and Contact lenses: assess surrounding orbital injuries and remove contact lenses.

D = Drugs, Diagnostic imaging, and Don'ts: administer antibiotics, analgesics, and antiemetics, obtain a CT of the orbit, and avoid MRIs or applying pressure.
E= Eye shield and Evacuate: protect the eye, consult ophthalmology, and transport to the OR quickly if indicated.[7] This mnemonic fits directly into the existing framework clinicians use to address life threats at presentation and is easily adapted into an efficient algorithm. Given the complexity of management, a structured approach using this method can help reduce delays in care. It is important to note that within this framework an early physical exam is critical to the algorithm.

A thorough physical exam can reveal signs that raise suspicion for OGIs while also identifying other surrounding traumatic injuries such as orbital fractures. Indications of OGI can include pupil irregularities, iris irregularities, iridodialysis, leakage of vitreous fluid, and restriction of extraocular movements.[8] Next, a fluorescein eye exam should be performed to evaluate for injuries to the corneal or conjunctival epithelium of the eye, demonstrated by areas of fluorescein uptake. The presence of a Seidel's sign, which appears as a dark blue stream within the fluorescein dye, indicates the leakage of vitreous fluid.[1] If physical exam findings, fluorescein exam, or imaging are suggestive of an OGI, the measurement of IOP should be avoided. Many of the current methods of tonometry rely on introducing a small force to the globe and measuring the resistance required to flatten the globe, and further pressure on the globe can lead to increased leakage of the globe contents.[9-11] Similarly, if a foreign object is noted, the object must not be removed in the emergency department as to avoid alterations in IOP and limit routes of entry for pathogens.[3] As demonstrated in this case study, the care team did not measure IOP due to concern for OGI. However, it should be noted that some cases of OGI's may have occult presentations, and pressures might be taken unknowingly. A high index of suspicion is important. In occult presentations, signs of OGI include decreased IOP (≤2 mmHg than the contralateral eye), a deepened anterior chamber with iris retraction, and vitreous hemorrhage.[12]

Computed tomography (CT) is the first-line recommended imaging modality for evaluation of OGIs. A pooled metanalysis of CT imaging reports a sensitivity of 77% and specificity of 94%.[13] However, in cases of occult OGIs in which the injury was not identified by the physical exam, the sensitivity and specificity may be slightly lower at 71% and 76%, respectively.[14] Because of this, in some cases surgical exploration might still be recommended even in the absence of positive imaging findings. Another imaging alternative is ultrasonography; however, ultrasound is relatively contraindicated as it is difficult to perform successfully while carefully avoiding pressure to the eye. If point-of-care-ultrasound (POCUS) can be performed successfully, the sensitivity and specificity of detecting globe rupture has been reported as 100% and 99.7%, respectively.[15] Regardless of choice in imaging, an expeditious consultation to ophthalmology or transfer to a comprehensive ophthalmic care center for evaluation of surgical intervention should be the primary goal in the management of OGIs in the emergency department.

There are a number of well reported prognostic factors in the literature that are significantly associated with final visual acuity and patient outcomes. Important prognostic factors in visual acuity include the zone of injury, displacement of the crystalline lens, retinal detachment, iris dialysis, hypotony, vitreous hemorrhage, and the visual acuity at presentation. The zones of the eye as it pertains to ocular trauma include: zone 1, an injury to the cornea or limbus; zone 2, an injury to the anterior sclera within 5 mm of the limbus; zone 3, an injury more than 5 mm posterior to the limbus.[16] A poor visual acuity at presentation, a zone 3 injury, and the other findings described are all predictors of poor outcomes in visual acuity.[5, 17] Additionally, the mechanism of injury plays an important role in the anatomical outcomes of globe injuries. OGI due to intraocular foreign bodies is associated with positive anatomical outcomes, while OGI due to rupture (blunt force) and penetration (sharp object) are associated with poor anatomical outcomes; anatomical outcome examples include phthisis bulbi or enucleation.[5] In this case study, the patient had an uncorrected visual acuity of 20/50 and a final visual acuity of 20/60 at post-operative day 4. Given the strong predictive value of visual acuity at presentation and zone of injury, this patient may be more likely to exhibit long-term favorable outcomes.

This case report presents interesting and unique physical exam findings of OGI that are not generalizable to all OGIs. Further research should be done to characterize the presentations and outcomes of various OGI cases. The patient had no recorded baseline in visual acuity, and it is unclear if visual acuity was already affected by the corneoscleral laceration or hyphema at presentation. Additionally, the patient was lost to outpatient follow-up after post-operative day 4, which limits the assessment of long-term outcomes in visual acuity. While post-operative visual acuity had returned to similar values noted at initial presentation, the collection of long-term follow-up data would have been helpful to better understand long-term outcomes in this patient and in OGIs more broadly. This case report details a less common and interesting presentation of OGI secondary to ocular trauma. Examples seen in this case include a peaked pupil, herniation of the iris through the defect

in the corneoscleral junction, as well as a hyphema. It is critical to use fluorescein eye exams to aid in the identification of OGIs so that measurement of intraocular pressures may be avoided. Should an obvious foreign body be present, objects should not be removed under the same principle in which we must avoid alterations to IOP while also limiting entry points for pathogens.[3] This case also highlights the importance of the use of eye protection in working or high-risk environments since many cases of foreign bodies to the eye are likely preventable with the use of proper eye protection. Despite limitations in follow-up, this case represents strict adherence to the principles of management in ocular trauma and a positive outcome in which a patient's vision and visual acuity were relatively maintained.

Clinical Teaching Guide

- Visible dark tissue at the cornea, or a limbal wound, should be considered a uveal prolapse and an open globe injury until proven otherwise.
- Avoid tonometry, manual manipulation of the eye or palpebra, and any other source of pressure to the globe if an open globe injury is suspected.
- The prognosis of an open globe injury can depend more on the zone of injury, visual acuity at presentation, or mechanism of trauma than on uveal prolapse alone.

References:

1. Romaniuk VM. Ocular trauma and other catastrophes. *Emerg Med Clin North Am*. 2013;31(2):399-411. doi:10.1016/j.emc.2013.02.003
2. Channa R, Zafar SN, Canner JK, Haring RS, Schneider EB, Friedman DS. Epidemiology of eye-related emergency department visits. *JAMA Ophthalmol.* 2016;134(3):312-319. doi:10.1001/jamaophthalmol.2015.5778
3. Pelletier J, Koyfman A, Long B. High risk and low prevalence diseases: Open globe injury. *Am J Emerg Med.* 2023;64:113-120. doi:10.1016/j.ajem.2022.11.036
4. Seery CW, Choudhry HS, Dastjerdi MH. Zone 1 trauma: wound dehiscence compared to primary trauma. *Int Ophthalmol*. 2024;44(1):74. doi:10.1007/s10792-024-02923-2
5. Puodžiuvienė E, Valeišaitė G, Žemaitienė R. Clinical characteristics, visual outcomes, and prognostic factors of open globe injuries. *Medicina (Kaunas)*. 2021;57(11):1198. doi:10.3390/medicina57111198
6. Peleja MB, da Cunha FB, Peleja MB, Rohr JT. Epidemiology and prognosis factors in open globe injuries in the Federal District of Brazil. *BMC Ophthalmol.* 2022;22(1):111. doi:10.1186/s12886-021-02183-z
7. Kroesen CF, Snider M, Bailey J, et al. The ABC's of ocular trauma: Adapting a familiar mnemonic for rapid eye exam in the pre-ophthalmic zone of care. *Mil Med*. 2020;185(Suppl 1):448-453. doi:10.1093/milmed/usz262
8. Bord SP, Linden J. Trauma to the globe and orbit. *Emerg Med Clin North Am.* 2008;26(1):97-vii. doi:10.1016/j.emc.2007.11.006
9. Machiele R, Motlagh M, Zeppieri M, Patel BC. Intraocular pressure. *In: StatPearls. Treasure Island (FL):* StatPearls Publishing; February 27, 2024. Accessed May 31, 2025. https://www.statpearls.com/point-of-care/23710
10. Demirci G, Erdur SK, Tanriverdi C, Gulkilik G, Ozsutçu M. Comparison of rebound tonometry and non-contact airpuff tonometry to Goldmann applanation tonometry. *Ther Adv Ophthalmol.* 2019;11:2515841419835731. doi:10.1177/2515841419835731
11. Perry M, Dancey A, Mireskandari K, Oakley P, Davies S, Cameron M. Emergency care in facial trauma--a maxillofacial and ophthalmic perspective. *Injury.* 2005;36(8):875-896. doi:10.1016/j.injury.2004.09.018
12. Chronopoulos A, Ong JM, Thumann G, Schutz JS. Occult globe rupture: diagnostic and treatment challenge. *Surv Ophthalmol.* 2018;63(5):694-699. doi:10.1016/j.survophthal.2018.04.001
13. Aljuhani G, Aljuhani N. Computed tomography accuracy and features in detecting open globe injuries in patients with ocular trauma: a systematic review and meta-analysis. *J Med Life.* 2025;18(1):20-28. doi:10.25122/jml-2024-0353
14. Arey ML, Mootha VV, Whittemore AR, Chason DP, Blomquist PH. Computed tomography in the diagnosis of occult open-globe injuries. *Ophthalmology*. 2007;114(8):1448-1452. doi:10.1016/j.ophtha.2006.10.051
15. Ojaghihaghighi S, Lombardi KM, Davis S, Vahdati SS, Sorkhabi R, Pourmand A. Diagnosis of traumatic eye injuries with point-of-care ocular ultrasonography in the emergency department. *Ann Emerg Med*. 2019;74(3):365-371. doi:10.1016/j.annemergmed.2019.02.001
16. Pieramici DJ, Sternberg P, Aaberg TM, et al. A system for classifying mechanical injuries of the eye (globe). The Ocular Trauma Classification Group. *Am J Ophthalmol*. 1997;123(6):820-831. doi:10.1016/s0002-9394(14)71132-8
17. Fujikawa A, Mohamed YH, Kinoshita H, et al. Visual outcomes and prognostic factors in open-globe injuries. *BMC Ophthalmol.* 2018;18(1):138. Published 2018 Jun 8. doi:10.1186/s12886-018-0804-4