

# UC Davis

## Dermatology Online Journal

### Title

Paraneoplastic plaque-like cutaneous mucinosis: a case report

### Permalink

<https://escholarship.org/uc/item/1rh2t3hg>

### Journal

Dermatology Online Journal, 21(2)

### Authors

Owen, Joshua L  
Word, Andrew P  
Vandergriff, Travis  
et al.

### Publication Date

2015

### DOI

10.5070/D3212024161

### Supplemental Material

<https://escholarship.org/uc/item/1rh2t3hg#supplemental>

### Copyright Information

Copyright 2015 by the author(s). This work is made available under the terms of a Creative Commons Attribution-NonCommercial-NoDerivatives License, available at <https://creativecommons.org/licenses/by-nc-nd/4.0/>

Peer reviewed

**Case presentation**

**Paraneoplastic plaque-like cutaneous mucinosis: a case report**

**Joshua L. Owen, BS, Andrew P. Word, MD, Travis Vandergriff, MD, Seemal R. Desai, MD**

**Dermatology Online Journal 21 (2): 5**

**Department of Dermatology, University of Texas Southwestern Medical Center**

**Correspondence:**

Joshua Owen  
5323 Harry Hines Blvd., Dallas, TX 75390-9069  
Phone: 214-648-3493; Fax: 214-648-5553  
Email: Joshua.Owen@UTSouthwestern.edu

---

**Abstract**

Plaque-like cutaneous mucinosis (PCM) is a rare disorder of dermal mucin deposition. Some patients with PCM will be found to have an associated malignancy. We report a 72-year-old man presenting with new onset pruritic, waxy-appearing erythematous and skin-colored papules and nodules coalescing into plaques on his shoulder, scalp, and forehead. Skin biopsy revealed cutaneous mucinosis. Despite conservative treatment, his skin lesions progressed and he was found to have an occult malignancy of pancreatobiliary origin. After several months of chemotherapy, his skin lesions showed progressive improvement. To our knowledge, this is the third reported case of paraneoplastic PCM and the first reported to occur in association with underlying adenocarcinoma of pancreatobiliary origin. PCM may occasionally represent a paraneoplastic dermatosis. This case highlights the importance of a search for occult malignancy in such patients.

**Keywords: cutaneous mucinosis, lichen myxedematosus, papular mucinosis, plaque-like cutaneous mucinosis, paraneoplastic**

**Introduction**

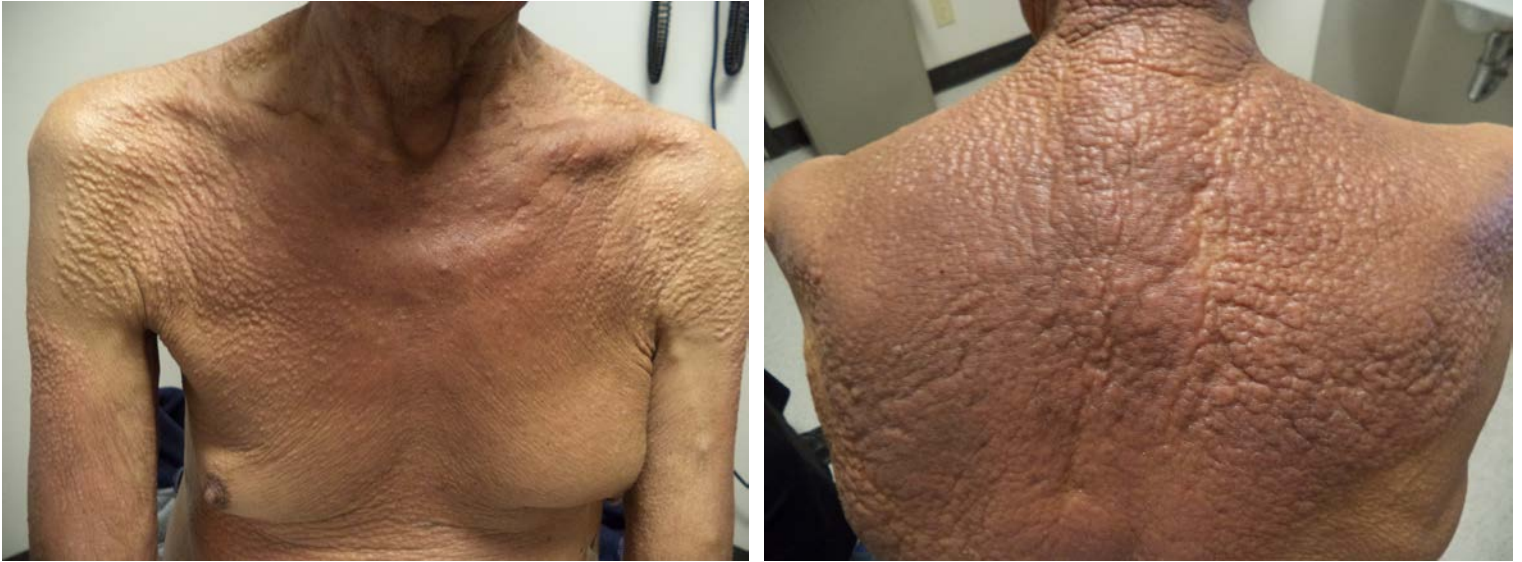Cutaneous mucinoses are a heterogeneous group of disorders characterized by dermal mucin deposition [1]. Plaque-like cutaneous mucinosis (PCM), a rare atypical variant of lichen myxedematosus (LM), or papular mucinosis, is characterized by multiple erythematous or hyperpigmented papules coalescing into plaques [2, 3].

Underlying malignancy has been reported in a subset of patients with cutaneous mucinoses, particularly scleromyxedema and PCM. Herein, we report a case of paraneoplastic PCM with an initially occult pancreatobiliary adenocarcinoma. Clinical improvement in skin lesions was observed with chemotherapy treatment of the adenocarcinoma.

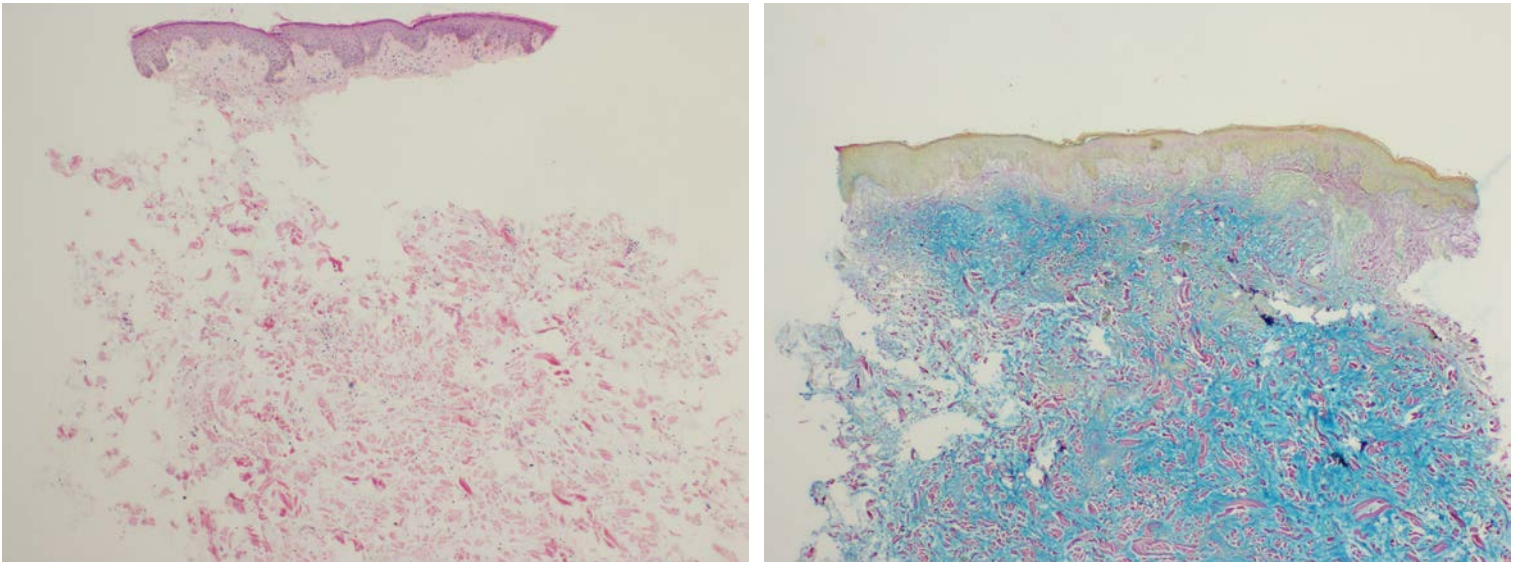
**Case synopsis**

A 72-year-old man with a history of recurrent hepatitis C virus cirrhosis after orthotopic liver transplant for hepatocellular carcinoma presented with new onset pruritic rash. Physical exam revealed waxy, erythematous, and skin-colored papules and nodules coalescing into rippled infiltrative plaques on the left shoulder, occipital scalp, and forehead (Figure- 1). Skin biopsies revealed an increase in the amount of interstitial mucin in the dermis, without increased cellularity, fibrosis, inflammatory

infiltrate, or neoplastic cells (Figure- 2A). The interstitial mucin was highlighted by colloidal iron staining (Figure- 2B). An elevated thyroid-stimulating hormone level was detected; levothyroxine was initiated, with correction of thyroid function within one month. Serum and urine protein electrophoresis revealed no monoclonal gammopathy. Potent topical steroids and oral antihistamines were prescribed.



**Figure 1.** Paraneoplastic plaque-like cutaneous mucinosis is shown in clinical photographs prior to initiation of chemotherapy. Chest (A) and upper back (B) demonstrate diffuse, waxy, and erythematous to skin-colored papules coalescing into plaques.



**Figure 2.** Skin biopsy from left posterior shoulder. Low power (20X) hematoxylin-eosin stain (A) and colloidal iron staining mucin (B). Abundant mucin deposition in the dermis without fibrosis is observed in both images, consistent with cutaneous mucinosis.

However, the skin lesions progressively spread to the chest, abdomen, back, posterior neck, and upper arms. Three months after initial presentation, pericardiocentesis was performed for cardiac tamponade, with cytology revealing metastatic adenocarcinoma of pancreatobiliary origin. Gemcitabine and cisplatin chemotherapy was initiated; within several months, the thickness of plaques on the back and neck decreased, along with resolution of individual papules on the arms.

## Discussion

Lichen myxedematosus (LM) is divided into three categories: diffuse (scleromyxedema), localized, and atypical [4]. Scleromyxedema is associated with underlying monoclonal gammopathy and a classic histologic triad of mucin deposition, fibroblast proliferation, and fibrosis. In contrast, localized LM lacks association with monoclonal gammopathy and exhibits variable fibroblast proliferation without fibrosis. Both scleromyxedema and localized LM occur in the absence of thyroid dysfunction [4]. Atypical LM includes scleromyxedema without monoclonal gammopathy, localized LM with monoclonal

gammopathy, localized LM with mixed features, and other nonspecified cases [4]. The nonspecified atypical LM group includes PCM [2, 3].

Underlying malignancy has been reported in a subset of patients with cutaneous mucinoses, particularly scleromyxedema and PCM. Scleromyxedema has been associated with a variety of hematologic and solid malignancies [4]. There have been 16 previous reports of PCM in the literature, two of which were associated with underlying adenocarcinomas [2]. In one case, PCM spontaneously resolved 7 years after mastectomy for breast adenocarcinoma [2]. In another case, PCM preceded the diagnosis of colon adenocarcinoma by 13 years. PCM cleared following chemoradiation therapy but later recurred despite continued remission of malignancy [2].

Consistent with a paraneoplastic process, our patient's skin lesions worsened with malignancy progression and improvement after chemotherapy initiation. Adenocarcinomas can produce and secrete mucin [5], possibly contributing to pathogenesis of PCM. Although the clinical presentation of our case suggested scleromyxedema, the histopathology was consistent with cutaneous mucinosis. Importantly, there was dermal mucin deposition but no increased cellularity or fibrosis. Additional features not consistent with scleromyxedema included absence of monoclonal gammopathy and involvement of the scalp [4]. Thyroid dysfunction as a cause was excluded given the progression of cutaneous lesions despite normalization of thyroid function [6]. The similarity of PCM to reticular erythematous mucinosis (REM) has been noted in the literature previously [2]. However, our patient lacked typical clinical characteristics of REM, such as photosensitive urticarial papules restricted to midline distribution. Histologically, dermal mucin deposition was present, but vascular dilation with perivascular and perifollicular lymphocytic infiltrate was absent [2, 3].

For the treatment of PCM, topical and systemic corticosteroids and antihistamines are ineffective, whereas antimalarials have shown occasional success [2, 3]. The mainstay of treatment of paraneoplastic PCM centers on treatment of the underlying malignancy.

To our knowledge, this is the third reported case of PCM associated with malignancy and the first with underlying adenocarcinoma of pancreatobiliary origin. As evidenced in our case, recognizing the rare association of cutaneous mucinoses with underlying malignancy can aid in timely detection and treatment of malignancy.

In conclusion, our case demonstrates the importance of the association between cutaneous mucinoses, particularly PCM, with underlying malignancy. The dermatologist plays a key role in the recognition of this association, aiding in earlier detection and treatment.

## References

1. Rongioletti F, Rebora A. Cutaneous mucinoses: microscopic criteria for diagnosis. *Am J Dermatopathol*. 2001;23(3):257-67. [PMID: 11391115]
2. Quimby SR, Perry HO. Plaquelike cutaneous mucinosis: its relationship to reticular erythematous mucinosis. *Journal of the American Academy of Dermatology*. 1982;6(5):856-61. [PMID: 7096649]
3. Wriston CC, Rubin AI, Martin LK, Kossard S, Murrell DF. Plaque-like cutaneous mucinosis: case report and literature review. *Am J Dermatopathol*. 2012;34(4):e50-4. [PMID: 22617136]
4. Rongioletti F, Rebora A. Updated classification of papular mucinosis, lichen myxedematosus, and scleromyxedema. *Journal of the American Academy of Dermatology*. 2001;44(2):273-81. [PMID: 11174386]
5. Yiannakou JY, Newland P, Calder F, Kingsnorth AN, Rhodes JM. Prospective study of CAM 17.1/WGA mucin assay for serological diagnosis of pancreatic cancer. *Lancet*. 1997;349(9049):389-92. [PMID: 9033465]
6. Jackson EM, English JC, 3rd. Diffuse cutaneous mucinoses. *Dermatol Clin*. 2002;20(3):493-501. [PMID: 12170882]