UC Irvine
Mediterranean Journal of Emergency Medicine & Acute Care

Title

A Case Report of Toxicity from Ingestion of a Hospital Antiseptic Solution Containing 1-Propanol and 2-Propanol

Permalink

https://escholarship.org/uc/item/23j2906q

Journal

Mediterranean Journal of Emergency Medicine & Acute Care, 4(1)

ISSN

2642-7168

Authors

Farah, Rita
Muffarij, Afif
ElZahran, Tharwat
et al.

Publication Date

2022-10-06

DOI

10.52544/J5.61818

Copyright Information

Copyright 2022 by the author(s).This work is made available under the terms of a Creative Commons Attribution License, available at https://creativecommons.org/licenses/by/4.0/

Peer reviewed

eScholarship.org Powered by the California Digital Library
University of California

DOI:10.52544/J5.61818
MedJEM
Case Report

A Case Report of Toxicity from Ingestion of a Hospital Antiseptic Solution Containing 1-Propanol and 2-Propanol

Rita Farah[1], Afif Muffarij[2], Tharwat El Zahran[2], Ziad Kazzi[2], Sandra Mrad[2]

[1]Department of Emergency Medicine, Emory School of Medicine, Atlanta, Georgia poison center, Atlanta, GA, USA
[2]Department of Emergency Medicine, American University of Beirut Medical Center, Beirut, Lebanon

ABSTRACT

In the midst of the COVID-19 pandemic, the increased risk of exposure to 1-propanol has led the United States Food and Drug Administration to issue a warning about toxicity of 1-propanol-contaminated brands of hand sanitizers. We report a mixed intoxication with 1-propanol and 2-propanol in a patient who unintentionally ingested approximately 300 mL of hospital topical antiseptic solution and who presented to the emergency department with nausea, vomiting, and decreased level of consciousness. The patient developed an anion gap metabolic acidosis without an osmolar gap, elevated serum lactate, and undetectable serum beta-hydroxybutyrate. One hour later, he developed chest pain and was found to have an ST-segment elevation myocardial infarction. The patient underwent urgent coronary angiography and stenting of the totally occluded mid-segment of the Left Anterior Descending coronary artery. The patient recovered and was discharged home after 7 days.

Key words: 1-propanol, 2-propanol, intoxication, myocardial infarction

BACKGROUND

The COVID-19 pandemic has increased the use of alcohol-based hand sanitizers. The resulting increase demand by consumers led to the introduction of a large number of products into the market, some of which were found to contain 1-propanol or methanol. In the first five months of 2020, American Association of Poison Control Centers reported 9,504, unintentional, alcohol-based hand sanitizer exposure cases in children aged less than 12 years.[1] Concerns with 1-propanol toxicity led the United States Food and Drug Administration (FDA), in June 2020, to issue warnings about 1-propanol-contaminated brands of hand sanitizers.[2] 1-propanol intoxication can cause metabolic acidosis, central nervous system (CNS) depression and death. We report here a case of unintentional poisoning with Sterilium®, a topical antiseptic composed of 1-propanol and 2-propranol that are colorless liquids with a sweet odor.[3,4]

Correspondence to:

Rita Farah

Department of Emergency Medicine,
Emory School of Medicine, Atlanta, GA
Georgia Poison Center, Atlanta, GA, USA
Email: rita.jean.farah@emory.edu

CASE REPORT

An 85-year-old male patient, with a past medical history of hypertension, coronary artery disease and coronary angioplasty, presented to the emergency department (ED) with decreased level of consciousness and emesis. The patient had accidentally ingested 30 minutes prior to presentation, 300 ml of a diluted solution of Sterillium® that is composed of 45 grams of 2-propanol, 30 grams of 1-propanol and 0.2 gram of mecetroniumetilsulfate per 100 grams. The disinfectant solution was obtained from the hospital during the patient's recent hospital admission for knee arthroplasty and was diluted with water and stored in a different container for household use. On arrival to the ED, the patient had decreased level of consciousness, was restless (GCS of 15), a temperature of 36.8 °C, a heart rate of 69 beats per minute, a blood pressure of 99/85 mm of Hg, a respiratory rate of 18 breaths per minute, and a pulse oximetry of 94% on room air. His blood glucose

was 146 mg/dl, and the rest of his examination was unremarkable.

Table 1 Patient's initial laboratory results in the Emergency Department

LABORATORY TEST	RESULT
White blood cells (/cu.mm)	9,500
Hemoglobin (g/dL)	10.4
Platelets (/cu.mm)	317,000
Sodium (mmol/L)	142
Chloride (mmol/L)	101
Bicarbonate (mmol/L)	21
Anion Gap	20
Serum creatinine (mg/dL)	0.8
Blood urea nitrogen (mg/dL)	18
Aspartate aminotransferase (IU/L)	19
Alanine aminotransferase (IU/L)	24
γ-glutamyl transpeptidase (IU/L)	61
Alkaline phosphatase (IU/L)	85
Lactate (mmol/L)	6.23
Measured serum osmolality (mOsm/kg)	297
Calculated serum osmolarity (mOsm/kg)	297
Ethanol (mg/dL)	0
Beta-hydroxybutyrate (mmol/L)	0
Troponin (ng/ml)	0.033
INR	1.1
PTT	30
Arterial Blood Gas	
pH	7.34
pCO2 (mmHg)	35.1
pO2 (mmHg)	133
HCO3- (mmol/L)	18.7

The initial electrocardiogram (ECG) showed normal regular sinus rhythm with no ST segment or T wave abnormalities and the chest radiograph was unremarkable. Initial laboratory results were remarkable for high anion gap metabolic acidosis with lactic acidosis (Table 1).

Initial emergency management included continuous cardiac monitoring, oxygen support with 2 liters oxygen via nasal cannula, intravenous bolus with two liters of normal saline, 80 mg of esomeprazole, 10 mg of intravenous metoclopramide, 8 mg of intravenous ondansetron, and 1 gram of intravenous paracetamol. One hour post arrival, the patient complained of chest pain and his repeat ECG showed an anterior ST-Elevation Myocardial Infarction (Figure 1). Urgent coronary angiography was performed and revealed a total occlusion in the mid-segment of the left anterior descending artery for which two drug-eluting stents were placed successfully. In the interventional lab, the patient became hypotensive and was started on a dopamine infusion. He was then transferred to the coronary care unit for observation. On hospital day 2, the patient's serum lactate decreased to 2.74 mmol/L and his metabolic acidosis resolved. His urine analysis showed trace ketones that disappeared in a repeat urine analysis 6 hours later. The patient was discharged home in stable condition one week later.

DISCUSSION

This case describes a mixed intoxication with 1-propanol and 2-propanol after an unintentional ingestion of the hand disinfectant solution (Sterilium®).

Sterilium® poisoning is of particular interest owing to the combined effect of two products: 1-propanol and 2-propanol. Severe and life-threatening intoxications with isolated 2-propanol and mixed intoxications with 1-propanol have been reported in the literature; however, in none of the reported cases intoxicated patients were diagnosed with a myocardial infarction following exposure to propranolol.[5-7] Vujasinović et al. reported a 37-year-old man who ingested a bottle of 500 mL of Monopronto Extra solution (27.6% of 1-propanol and 36.1% of 2-propanol) during a visit to his ill father at a hospital.[6] The patient developed anxiety, dysarthria, ataxia, loss of consciousness,

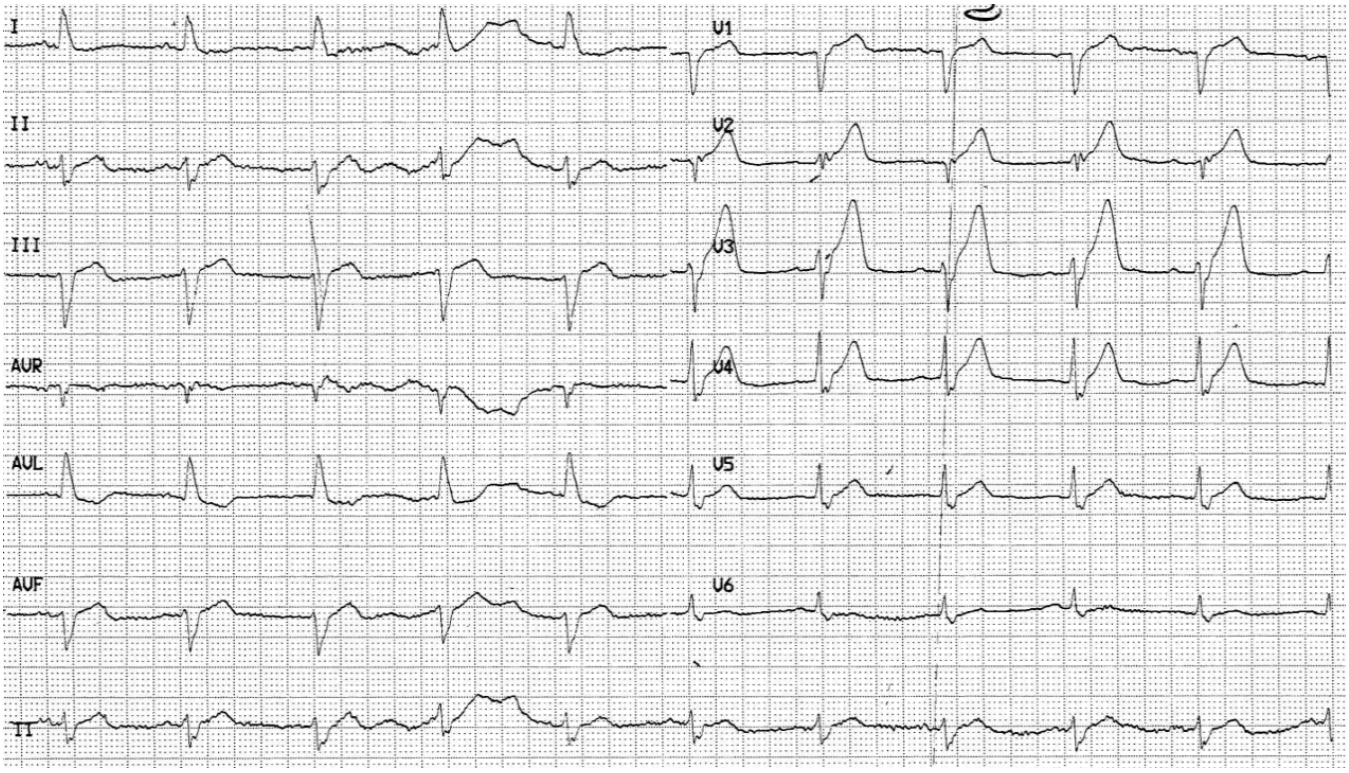

Figure 1 Electrocardiogram one hour following emergency

and respiratory failure requiring endotracheal intubation. This patient was discharged without any sequelae three days later. The authors concluded that 1-propanol and 2-propanol poisoning presents early with mixed acidosis and elevated anion gap and only later with ketonuria. Skop et al reported about a 21-year-old female who died after intentional ingestion of a mixed 1-propanol and 2 -propanol from an antiseptic solution. Autopsy findings revealed extended hemorrhagic lung edema, brain edema and shock kidneys.[7]

2-propanol (or isopropyl alcohol) is a colorless liquid that is commonly found in household and personal care products. It is rapidly absorbed within 15-30 minutes of ingestion. It is metabolized by hepatic alcohol dehydrogenase (ADH) to form acetone. In humans, the half-life of 2-propanol ranges between 2.5 and 8.0 hours; that of acetone averages about 22 hours. Ethanol and 1-propanol prolong the elimination of 2-propanol due to their higher affinity towards ADH. Consequently, concomitant ingestion will delay the metabolism of 2-propanol to acetone [5]. Although 2-propanol is not considered as toxic as methanol, ingestion of about 150 to 240 mL may be life-threatening.[8]

Depending on the amount ingested, symptoms of 2-propanol toxicity may range from gastrointestinal manifestations including nausea, vomiting, abdominal pain, hemorrhagic gastritis, and hematemesis to CNS effects including dizziness, headaches, confusion, stupor, and coma.[9] Patients with intoxication can have acute myopathy and may present with hypotension due to cardiac depression and vasodilatation.[10] Although 2-propanol was identified as the main agent responsible for CNS depression, Alexander et al. suggested that acetone may also contribute to CNS effects and coma.[11]

1-propanol is a colorless liquid that is excreted by the kidneys and lungs. Its elimination half-life is suggested to be lower than that of 2-propanol.[5] Furthermore, substandard hand sanitizers are a new source of exposure to 1-propanol and the FDA listed 1-propanol containing hand sanitizers on the Do-Not-Use list (https://www.fda.gov/consumers/consumer-updates/your-hand-sanitizer-fdas-list-products-you-should-not-uses). Acute 1-propanol ingestion may also cause nausea, vomiting, abdominal cramps, diarrhea, and somnolence

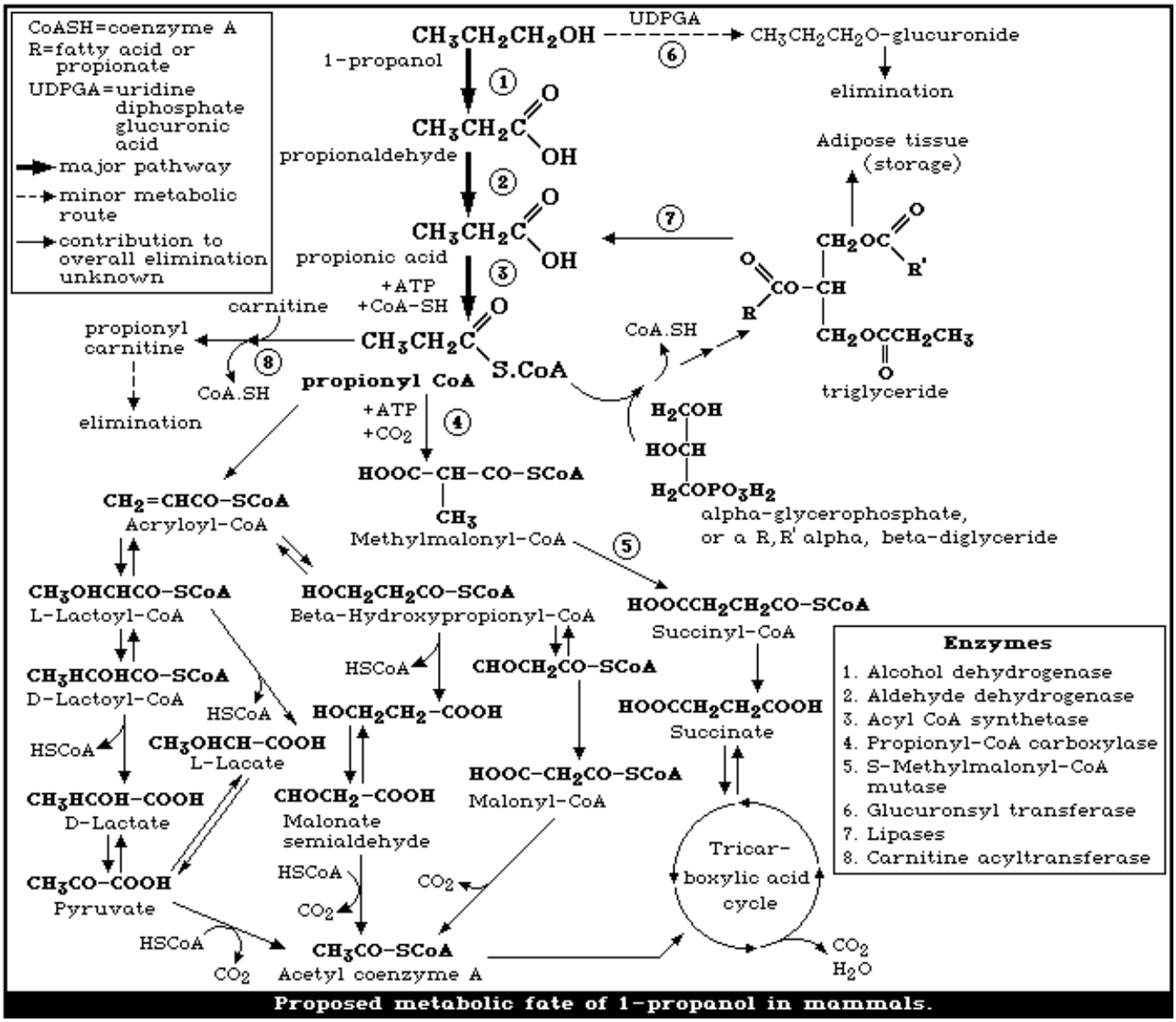

Figure 2 Metabolism of 1- propanol. *(Reproduced from World Health Organization. 1-propanol. Environmental Health Criteria 102; 1990. Available from https://www.inchem.org/documents/ehc/ehc/ehc102.htm)*

or coma. Animal studies indicate that the CNS depressant effects of 1-propanol are two to four times as potent as ethanol.[12] It is metabolized by ADH to propionic acid, which enters the citric acid cycle as a coenzyme A conjugate.[6] Propionic acid can form a coenzyme A conjugate that may enter different pathways for further metabolism such as the tricarboxylic acid cycle, lactate pathway and methylmalonyl pathway.[6] In the lactate pathway, the propionyl-CoA is dehydrogenated to acrylolyl-CoA, alpha-hydration gives L-lactoyl-CoA, which is hydrolyzed to lactate (Figure 2). Hence, in our patient high anion gap metabolic acidosis was seen with lactic acidosis. It is worth mentioning that 1-propanol is known to have a higher affinity for ADH than 2-propanol. Consequently, concomitant ingestion of 1-propanol will delay the metabolism of 2-propanol to acetone; the dose is sufficient to saturate ADH.[5]

Our hospital laboratory uses the ultraviolet spectrophotometric method to measure the beta-hydroxybutyrate level in serum and not the acetone level. A urine analysis that was done 24 hours following the presentation to our hospital showed traces of ketones that can be explained by the formation of the acetone metabolite of 2-propanol. This result is consistent with the previously discussed late ketonuria obtained in case of 1-propanol and

2-propanol co-ingestion.[6]

There is no clear correlation between ST elevation myocardial infarction after co-ingestion of 1-propanol and 2-propanol. The proposed mechanism could be due to coronary vasospasm, decreased fibrinolysis, and an enhanced prothrombotic state caused by the acute intoxication and sympathetic overstimulation. Our patient already had a history of coronary artery disease with angioplasty, which puts him at a higher risk for myocardial infarction in any stress induced event. Biyik et al. reported a case of myocardial infarction following acute binge drinking in a previously healthy adolescent [13]. We estimate that our patient ingested 45 grams of 2-propanol and 30 grams of 1-propanol. It has been demonstrated that relatively large doses of alcohol stimulate thromboxane-mediated activation of platelets, and activate the inhibitors of plasminogen in the plasma. In addition, the consumption of 40 to 50 grams of alcohol can inhibit fibrinolytic activity [14].

CONCLUSION

1-propanol and 2-propanol poisoning may be associated with an early onset metabolic and lactic acidosis followed by delayed ketonuria. This case highlights the need to raise awareness for safe storage of chemicals in hospitals and at home.

Funding & Conflicts of Interest: Authors declare no conflicts of interest or sources of funding.

REFERENCES

1. Mahmood A, Eqan M, Pervez S, et al. COVID-19 and frequent use of hand sanitizers; human health and environmental hazards by exposure pathways. Sci Total Environ. 2020;742:140561. doi: 10.1016/j.scitotenv.2020.140561

2. Coronavirus (COVID-19) Update: FDA Reiterates Warning About Dangerous Alcohol-Based Hand Sanitizers Containing Methanol, Takes Additional Action to Address Concerning Products. FDA. 2020. Accessed July 31, 2021. https://www.fda.gov/news-events/press-announcements/coronavirus-covid-19-update-fda-reiterates-warning-about-dangerous-alcohol-based-hand-sanitizers

3. Propanol, 2- (EHC 103, 1990). Accessed July 28, 2021. http://www.inchem.org/documents/ehc/ehc/ehc103.htm

4. World Health Organization. 1-propanol. Environmental Health Criteria 102; 1990. Accessed July 28, 2021. http://www.inchem.org/documents/ehc/ehc/ehc102.htm

5. Blanchet B, Charachon A, Lukat S, Huet E, Hulin A, Astier A. A case of mixed intoxication with isopropyl alcohol and propanol-1 after ingestion of a topical antiseptic solution. Clin Toxicol. 2007;45(6):701-4. doi: 10.1080/15563650701517285

6. Vujasinović M, Kočar M, Kramer K, Bunc M, Brvar M. Poisoning with 1-propanol and 2-propanol. Hum Exp Toxicol. 2007;26(12):975-8. doi: 10.1177/0960327107087794

7. Skopp G, Gutmann I, Schwarz C-S, Schmitt G. An unnatural death by propan-1-ol and propan-2-ol. Int J Legal Med. 2016;130(4):975-80. doi: 10.1007/s00414-015-1302-3

8. Mégarbane B, Villa A. Poisoning with ethanol and 2-propanol-based hand rubs: give Caesar what belongs to Caesar! Neurocrit Care. 2019;30(1):226-8. doi: 10.1007/s12028-010-9353-2

9. Lacouture PG, Wason S, Abrams A, Lovejoy FH. Acute isopropyl alcohol intoxication. Am J Med. 1983;75(4):680-6. doi: 10.1016/0002-9343(83)90456-4

10. Gaudet MP, Fraser GL. Isopropanol ingestion: Case report with pharmacokinetic analysis. Am J Emerg Med. 1989;7(3):297-9. doi: 10.1016/0735-6757(89)90174-5

11. Alexander CB, McBay AJ, Hudson RP. Isopropanol and isopropanol deaths - ten years' experience. J Forensic Sci. 1982;27(3):541-8.

12. Hand Sanitizer Information. FDA. Accessed July 31, 2021. https://www.fda.gov/media/144212/download

13. Biyik I, Ergene O. Acute myocardial infarction associated with heavy alcohol intake in an adolescent with normal coronary arteries. Cardiol Young. 2006;16(2):190-2. doi: 10.1017/S1047951106000187

14. Van De Wiel A, Van Golde PM, Kraaijenhagen RJ, Von Dem Borne PAK, Bouma BN, Hart HC. Acute inhibitory effect of alcohol on fibrinolysis: Alcohol and fibrinolysis. Eur J Clin Invest. 2001;31(2):164-70. doi: 10.1046/j.1365-2362.2001.00773.x