

UC Merced

Proceedings of the Annual Meeting of the Cognitive Science Society

Title

Assessing the Problem-Solving Abilities of Patients with Frontal Lobe Lesions Using a Real World Travel Planning Task

Permalink

<https://escholarship.org/uc/item/3wq28217>

Journal

Proceedings of the Annual Meeting of the Cognitive Science Society, 28(28)

ISSN

1069-7977

Authors

Hoshino, Lisa Casagrande
Goel, Vinod
Grafman, Jordan
et al.

Publication Date

2006

Peer reviewed

Assessing the Problem-Solving Abilities of Patients with Frontal Lobe Lesions Using a Real World Travel Planning Task

Lisa Casagrande Hoshino (ldcasa@yorku.ca)

Vinod Goel (vgoel@yorku.ca)

Department of Psychology, York University
4700 Keele St., Toronto, ON M3J 1P3 Canada

Vanessa Raymont (vnraymont@bethesda.med.navy.mil)

Jordan Grafman (grafmanj@ninds.nih.gov)

National Institute of Neurological Disorders and Stroke / National Institute of Health
Bethesda, Maryland 20824 USA

Keywords: planning; problem-solving; prefrontal cortex

Introduction

It is widely accepted that lesions to the frontal lobes lead to deficits in planning and problem solving in real-world situations (Burgess, 2000; Goel & Grafman, 2000). However, very little is known about the differential involvement of left and right prefrontal cortex in planning problems. Goel (2002) has suggested that patients with lesions to the right prefrontal cortex may be particularly impaired in real-world planning tasks. To test this hypothesis we investigated the planning abilities of neurological patients with focal lesions to the right or left prefrontal cortex using a "Travel Planning Task" designed to simulate a real world planning problem scenario.

Method

Eighteen male patients with unilateral frontal lobe lesions (7 left and 11 right) participated in the study. Patients were recruited from the Vietnam Head Injury population through the National Institute of Health (NIH) in Bethesda, Maryland. All veterans were Americans of similar socio-economic backgrounds. Patients were matched for age and education with 9 normal male controls.

The task involves assisting an Italian couple to plan a one week vacation in the United States. Subjects are given information pertaining to their jobs and interests, and a binder with all necessary travel information (flights, maps, etc.). Subjects may design the vacation in any way that they see fit while keeping budgetary constraints and the interests of the couple in mind. An experimenter is present to answer questions and do math calculations. Subjects are asked to vocalize all fragments of thoughts they are attending to as they plan. Sessions are videotaped and data is analyzed using a verbal protocol analysis.

Results and Discussion

Raw data was transcribed and coded by two raters blind to subject groupings with high inter-rater reliability ($r=.89$). Plans were evaluated for their overall quality (i.e., completeness and appropriateness) and a score from 1-5 was given. Figure 1 shows the mean quality of plan scores for patients and controls. A one-way ANOVA revealed significant group differences, $F(2,26) = 4.197, p = .027$. Tukey post hoc comparisons showed that only patients with right frontal lesions produced significantly worse quality of plans than normal controls ($p=.035$).

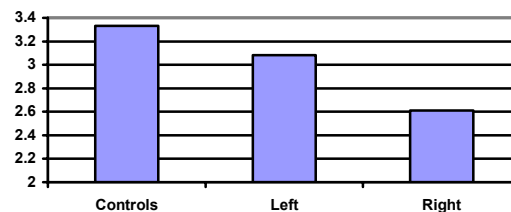


Figure 1. Mean quality of plan scores

Consistent with the hypothesis, when tasks are loosely constrained and more characteristic of real world scenarios, patients with right frontal lesions present significantly impaired planning abilities compared to controls.

Acknowledgements

This research was funded in part by a CIHR grant to Vinod Goel.

References

- Burgess, P. W. (2000). Strategy application disorder: The role of the frontal lobes in human multitasking. *Psychological Research, 63*, 279-288.
- Goel, V. & Grafman, J. (2000). Role of the right prefrontal cortex in ill-structured planning. *Cognitive Neuropsychology, 17*, 4, 15-436.
- Goel, V. (2002). Cognitive and neural basis of planning. In *Encyclopedia of cognitive science*. London: Macmillan.