

UC Davis

Dermatology Online Journal

Title

Red puffy hand syndrome mistaken for inflammatory arthritis

Permalink

<https://escholarship.org/uc/item/47d993kd>

Journal

Dermatology Online Journal, 26(6)

Authors

Barton, Michael
Fett, Nicole

Publication Date

2020

DOI

10.5070/D3266049321

Copyright Information

Copyright 2020 by the author(s). This work is made available under the terms of a Creative Commons Attribution-NonCommercial-NoDerivatives License, available at <https://creativecommons.org/licenses/by-nc-nd/4.0/>

Peer reviewed

Red puffy hand syndrome mistaken for inflammatory arthritis

Michael Barton MD, Nicole Fett MD MSCE

Affiliations: Oregon Health & Science University, Department of Dermatology, Portland, Oregon, USA

Corresponding Author: Michael Barton, OHSU Department of Dermatology, Oregon Health & Science University, 3303 South Bond Avenue, Portland, OR 97239, Tel: 503-418-3376, Email: bartomi@ohsu.edu

Abstract

Red puffy hand syndrome is an uncommon clinical manifestation of intravenous drug abuse, which presents with bilateral, painless and non-pitting erythema and edema of the dorsal hands. The pathophysiology is believed to primarily be the result of lymphatic blockage from either direct toxicity of the injected drug, drainage of impurities, or infection complications. A woman in her 40's with remote intravenous drug use presented with over a decade of fixed, painless erythema and swelling of bilateral dorsal hands. Owing to an elevated rheumatoid factor, which would later be attributed to patient's untreated hepatitis C, these findings were mistaken for rheumatoid arthritis and unnecessarily treated with methotrexate and prednisone. Upon proper recognition of her underlying Red puffy hand syndrome, systemic medications were discontinued and appropriate care was initiated with lymphedema decongestion and occupational therapy. Red puffy hand syndrome, albeit rare, is an important manifestation of intravenous drug abuse; its recognition will spare patients from unnecessary systemic treatments.

Keywords: intravenous drug abuse, hand erythema, edema

Introduction

Red puffy hand syndrome is an uncommon clinical manifestation of intravenous drug abuse, which presents with bilateral, painless and non-pitting erythema and edema of the dorsal hands [1]. It is a rare entity that may be mistaken for other similar appearing disorders such as systemic sclerosis,

rheumatoid arthritis, or erythromelalgia. We present a patient with a past medical history full of specious information leading to unnecessary treatments. Our patient ultimately was diagnosed with red puffy hand syndrome.

Case Synopsis

A woman in her 40's presented with a 10-year history of persistent and progressive redness and swelling of her bilateral hands. No worsening was noted with exposure to cold or heat. She denied signs of Raynaud phenomenon and never developed digital ulcerations. The edema caused difficulties with gripping and dexterity, but was not associated with joint pain. Her rheumatoid factor was positive and over the years she had been treated with methotrexate and prednisone for presumed rheumatoid arthritis without improvement. Her medical history was notable for a history of untreated hepatitis C virus (HCV), polycythemia vera, and a remote history of intravenous substance abuse.

Clinical examination (**Figure 1**) revealed symmetric erythema and boggy edema of the dorsal hands and fingers. Hand elevation did not affect the edema. Distal digital pitting was absent. No nailfold capillary changes were appreciated. Laboratory workup including complete blood count, complete metabolic panel, antinuclear antibodies, cryoglobulins, and anti-cyclic citrullinated peptide antibodies was unremarkable. Rheumatoid factor was elevated. Neither erosions nor articular abnormalities were detected on left hand X-ray. A biopsy specimen was obtained from the left dorsal

index finger which revealed only sparse perivascular lymphocytic dermatitis with focal spongiosis with rare dyskeratosis and telangiectasias (**Figures 2, 3**). Neither vacuolar interface changes nor closely packed, hyalinized collagen bundles were appreciated. Colloidal iron stain highlighted trace interstitial mucin. The patient was advised to trial compression gloves which resulted in noticeable improvement with consistent use. Additionally, our patient was referred to hand and occupational therapy department for repeated sessions of manual lymphedema decongestion. Treatment of underlying hepatitis C virus was also recommended. Given the chronicity, asymptomatic and persistent nature, the patient's history of intravenous drug use, and the relatively unremarkable biopsy results, a diagnosis of red puffy hand syndrome was made.

Case Discussion

Red puffy hand syndrome was first described in 1965 by Dr. Hans Abeles who was Commissioner of Health for the Department of Corrections in New York City [1]. He began noticing contour changes of the dorsal aspects of the bilateral hands in several incarcerated

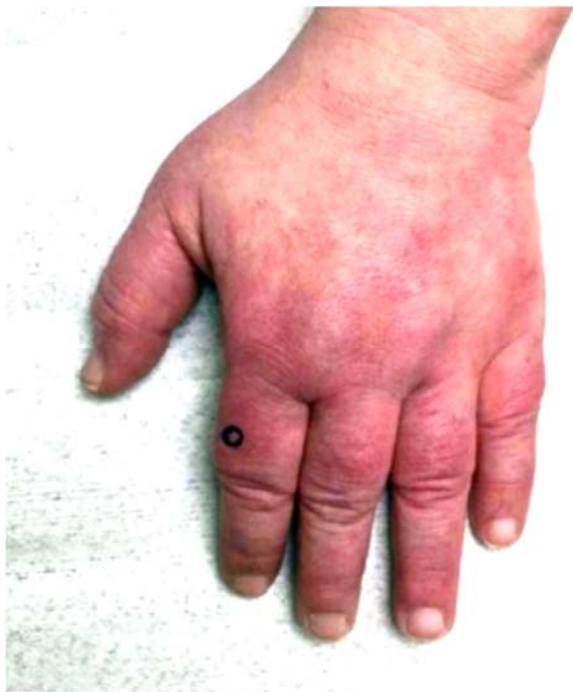

Figure 1. Clinical examination revealing erythema and edema of the left dorsal hand and fingers with biopsy site marked. Similar findings noted on right hand.

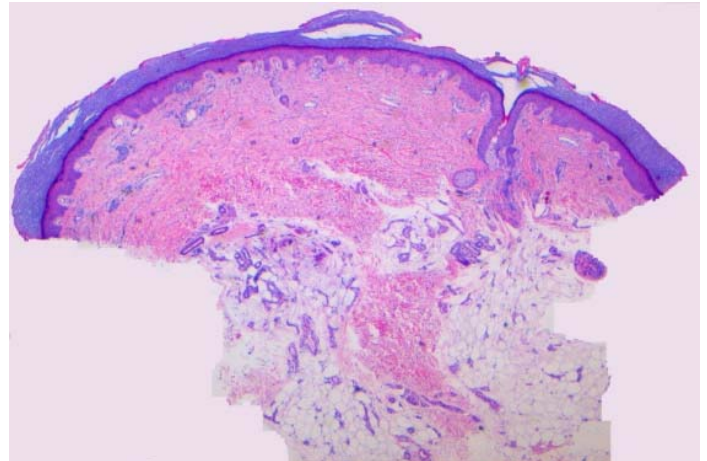


Figure 2. H&E staining showing a sparse perivascular lymphocytic infiltrate with focal spongiosis, rare dyskeratosis and telangiectasias, 2.5x.

individuals with histories of intravenous drug abuse. Presentation typically consists of bilateral, painless, and non-pitting edema of the dorsal hands, which at times extends proximally to the forearms. These changes are felt to be specific for intravenous drug use (IVDU), with estimates of red puffy hand syndrome affecting between 7 to 16% of intravenous drug users [2]. Initial presentation can appear during or years after IVDU, which highlights the importance of inquiring about previous substance use. These changes are often misdiagnosed and as a result may persist for years to decades before a history of IVDU and the correct diagnosis is discovered. Risk factors for the development of red puffy hands include female gender, injection in the hands, absence of tourniquet use, and poor antiseptic technique [2, 3].

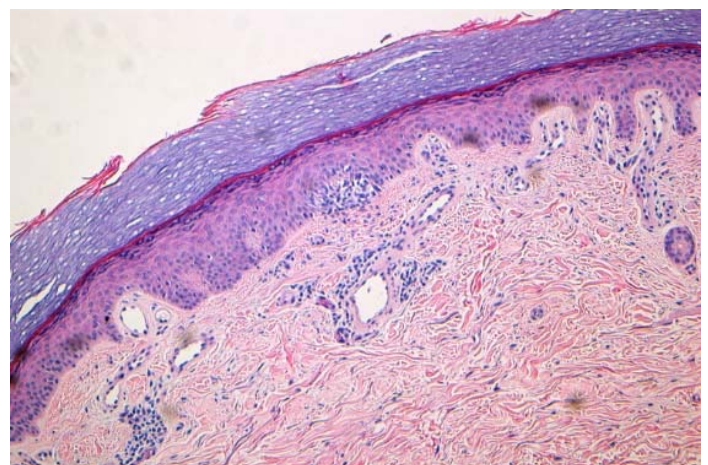


Figure 3. Sparse perivascular lymphocytic dermatitis with focal spongiosis, rare dyskeratosis and telangiectasias. H&E, 10x.

The pathophysiology is believed to be the result of lymphatic blockage from either direct toxicity of the injected drug, drainage of impurities, or infectious complications [4, 5]. Venous impairment may also play a lesser role. Treatment is geared toward overcoming the increased hydrostatic pressure of the affected vessels with elastic compression garments, lymphedema physical therapy, and manual lymphatic massage [2, 6].

Erythromelalgia is also accompanied by redness and swelling of the hands, but as the name implies is almost always associated with burning pain, is typically exacerbated by warm temperatures, and has a waxing and waning course. Rheumatoid arthritis often presents with pain, stiffness, and swelling of the metacarpophalangeal, wrist, and proximal interphalangeal (PIP) joints. In the absence of inflammatory arthritis symptoms and erosions, our patient's elevated rheumatoid factor was more likely attributed to HCV.

Although red puffy hand syndrome can mimic systemic sclerosis, especially the early edematous phase, an overwhelming majority of both limited and diffuse cutaneous systemic sclerosis patients have a history of Raynaud phenomenon, positive antinuclear antibodies, and development of

sclerodactyly. In addition, patients with red puffy hand syndrome lack nailfold capillary dilation and distal digital ulceration.

Theoretically, one could entertain vascular sludging in the setting of patient's polycythemia vera, but given the fixed nature without findings of vascular compromise this seems much less likely. To the author's knowledge there have been no prior cases reported of red puffy hand syndrome associated with polycythemia vera.

Conclusion

In conclusion, red puffy hand syndrome is recognized by fixed, symmetric, painless erythema and edema of the hands in patients with an active or past history of IVDU. It is a rare entity that may be confused with systemic sclerosis, rheumatoid arthritis, or erythromelalgia. Recognition of red puffy hand syndrome is important to spare patients from unnecessary systemic treatments.

Potential conflicts of interest

The authors declare no conflicts of interests.

References

1. Abeles H. Puffy-hand sign of drug addiction. *N Engl J Med*. 1965; 273:1167. [DOI: 10.1056/nejm196511182732118].
2. Chouk M, Vidon C, Deveza E, et al. Puffy hand syndrome. *Joint Bone Spine*. 2017;84:83-85. [PMID: 27269656].
3. Andresz V, Marcantoni N, Binder F, et al. Puffy hand syndrome due to drug addiction: a case-control study of the pathogenesis. *Addiction*. 2006;101:1347-51. [PMID: 16911735].
4. Neviasser RJ, Butterfield WC, Wieche DR. The puffy hand of drug addiction: a study of the pathogenesis. *J Bone Joint Surg Am*. 1972;54:629-33. [PMID: 5055159].
5. Vivaldelli E, Sansone S, Maier A, et al. Puffy hand syndrome. *Lancet*. 2017;389:298. [PMID: 27524395].
6. Arrault M, Vignes S. Puffy hand syndrome in drug addiction treated by low-stretch bandages. *Ann Dermatol Venereol*. 2006;133:769-72. [PMID: 17072191].