

UC Davis

Dermatology Online Journal

Title

Hereditary angioedema: 44 years of diagnostic delay

Permalink

<https://escholarship.org/uc/item/5cf802wr>

Journal

Dermatology Online Journal, 22(4)

Authors

Peterson, MP
Bygum, A

Publication Date

2016

DOI

10.5070/D3224030628

Copyright Information

Copyright 2016 by the author(s). This work is made available under the terms of a Creative Commons Attribution-NonCommercial-NoDerivatives License, available at <https://creativecommons.org/licenses/by-nc-nd/4.0/>

Letter

Hereditary angioedema: 44 years of diagnostic delay

MP Petersen and A Bygum MD

Dermatology Online Journal 22 (4): 20

Department of Dermatology and Allergy Centre, Odense University Hospital.

Correspondence:

Anette Bygum, M.D.
Department of Dermatology and Allergy Centre, Odense University Hospital
Odense, Denmark
Telephone +4565411803
Fax number +4566123819
E-mail: anette.bygum@rsyd.dk

Abstract

We report a 64-year-old man who suffered from recurrent visible swelling attacks since the age of 20 as well as episodes with severe upper airway edema, resulting in 4 emergency tracheotomies. Eventually after 44 years he was diagnosed with hereditary angioedema (HAE) type II. The aims of this report is to emphasize the importance of awareness concerning HAE, which does not respond to traditional anti-allergic therapy, and remind physicians to test for functional C1-INH deficiency.

Keywords: Hereditary angioedema, C1-inhibitor, diagnostic delay, asphyxia.

Introduction

Hereditary angioedema (HAE) is a rare autosomal dominant and potentially life threatening disease, characterized by episodes of edema of the skin, mucosa, and viscera. HAE can be divided into three primary types: Type I with quantitative deficiency of Complement C1 inhibitor (C1-INH), type II with dysfunctional C1-INH, or HAE with normal C1-INH [1]. Because of the variety of the clinical manifestations and common unfamiliarity among medical staff, HAE is often misdiagnosed for a long time and therefore not appropriately treated [2]. A correct diagnosis and treatment could be life saving for patients with HAE.

Case synopsis

A 64-year-old man was diagnosed with HAE based on functional C1-INH deficiency. He experienced his first emergency tracheotomy in 1970 when he was 20 years old. Approximately 1 year later he was hospitalized with sudden onset of facial swelling and was treated with intravenous corticosteroid, antihistamine, and adrenaline subcutaneously. He was discharged with an outpatient follow-up to clarify the etiology behind his swelling episodes. He went through an 8-day inpatient admission in which his concentration of C1-INH was 173 AU [ref; 66-113] and HAE was dismissed as a diagnosis. Two years later he was again hospitalized with a swelling involving his upper airway causing speaking difficulties. He was treated intravenously with corticosteroid, antihistamine and calcium but didn't respond and became cyanotic and consequently had his second emergency tracheotomy. He was transferred to the university hospital and placed on a strict elimination diet, which he carried out for one year. He was later trained in giving self-injection of subcutaneous adrenaline in case of severe swelling attacks, but didn't find it very helpful.

In 1978 he was hospitalized with tightness of his throat and respiratory difficulties. During the hospitalization he was treated with adrenaline, antihistamine, and corticosteroid. He was tested again for C1-INH deficiency (C1-INH: 189 AU [ref; 80-140]) and C4: 12 AU [ref; 40-135]); further allergologic examinations were performed with skin prick test, which came out

positive for brewers yeast. A provocation with brewers yeast and beer was however negative. Subsequently he started therapy with tranexamic acid 1g three times daily, with doubtful efficacy.

In 1988 he got a severe attack of pharyngeal edema and was treated with tranexamic acid and released the next day, even though there was still neck edema. After this episode he had further 4 hospitalizations with edema treated with a combination of corticosteroids, antihistamines, tranexamic acid, and adrenaline.

He had his third emergency tracheotomy in 1993 owing to severe respiratory deficiency caused by throat edema. In the years 2006 to 2013 he experienced swelling attacks approximately every third month and in 2013 he experienced a severe attack requiring ICU observation. In 2014 he was finally referred to the National HAE Centre and diagnosed with HAE type II, based on his classic history and blood testing showing C1-INH 0.45 g/L [ref; 0.21–0.39], functional C1-INH 24% [ref; 70–130%], complement C1q 0,71 $\mu\text{mol/L}$ [0,37 – 0,61], and complement C4 < 0.06 g/L [ref; 0,1-0.4].

Further examination revealed a mutation (c.1397g>a) in *SERPING1* confirming HAE. No other affected family members could be identified. He was supplied with C1-INH concentrate to be used in future swellings. The patient's hospitalizations are shown in figure 1.

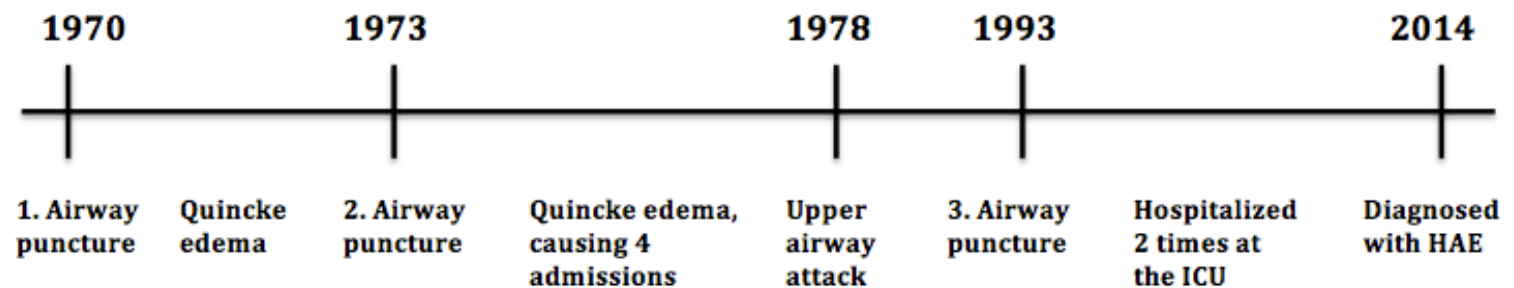


Figure 1. Timeline

Discussion

HAE can be a diagnostic challenge and in this case the diagnostic delay was very long. Diagnostic delay is a severe issue in the treatment of patients with HAE [3]. Patients with undiagnosed HAE have a 3-fold to 9-fold higher risk of asphyxiation compared to diagnosed patients [4]. A recent study showed a mean diagnostic delay of 12.1 years [range 0–72] in HAE [5]. Diagnosis of type II HAE is further challenging, as it requires measurement of functional C1-INH. The case history illustrates, that some physicians in fact thought about the correct diagnosis, but did not initiate testing for functional deficiency. Patients with HAE type II may have elevated values of C1-INH, as this case also illustrates.

Hereditary angioedema type II affects approximately 15% of the patients with HAE, which is why the physicians should measure C4 and antigenic and functional C1-INH if they suspect C1-INH deficiency; this diagnosis should not be excluded by normal or high C1-INH levels [6] (Figure 1).

Not unexpectedly, a recent study documented a noticeable difference in the median age at diagnosis between patients with HAE type I (25 years) and type II (31 years) [2].

Adrenaline is not effective in the treatment of HAE, and it can have many potential side effects [7]. Neither corticosteroids nor antihistamines are effective for the swellings in HAE patients; this has consistently been observed and is a part of the diagnostic criteria [8]. Hereditary angioedema can occur sporadically, which of course makes the diagnosis even more difficult. De novo mutations account for 25% of HAE patients [9]. In this subgroup physicians need to be even more aware of the symptoms of HAE. Because of the complexity of HAE, these patients should be referred to a specialist, who has experience in the disorder [10].

References

1. Bork K. Diagnosis and treatment of hereditary angioedema with normal C1 inhibitor. *Allergy Asthma Clin Immunol* 2010 Jul 28;6(1):15. [PMID: 20667118]
2. Zanichelli A, Arcoleo F, Barca MP, et al. A nationwide survey of hereditary angioedema due to C1 inhibitor deficiency in Italy. *Orphanet J Rare Dis* 2015 Feb;6;10:11. [PMID: 25758562]
3. Betschel S, Badiou J, Binkley K, et al. Canadian hereditary angioedema guideline. *Allergy Asthma Clin Immunol* 2014 Oct;24;10(1):50. [PMID: 25352908]
4. Bork K, Hardt J and Witzke G. Fatal laryngeal attacks and mortality in hereditary angioedema due to C1-INH deficiency. *J Allergy Clin Immunol* 2012 Sep;130(3):692–7. [PMID: 22841766]

5. Speletas M, Szilagyi A, Psarros F, et al. Hereditary angioedema: molecular and clinical differences among European populations. *J Allergy Clin Immunol* 2015 Feb;135(2): 570–3. [PMID: 25258140]
6. Bowen T, Cicardi M, Farkas H, et al. 2010 International consensus algorithm for the diagnosis, therapy and management of hereditary angioedema. *Allergy Asthma Clin Immunol* 2010 Jul;28;6(1):24. [PMID: 20667127]
7. Rye Rasmussen EH, Bindslev-Jensen C, Bygum A. Angioedema – assessment and treatment. *TidsskrNor Laegeforen* 2012 Nov;12;132(21):2391–5. [PMID: 23160589]
8. Zuraw BL, Bork K, Binkley KE, et al. Hereditary angioedema with normal C1 inhibitor function: consensus of an international expert panel. *Allergy Asthma Proc* 2012 Nov-Dec;33:145–56. [PMID: 23394603]
9. Pappalardo E, Cicardi M, Duponchel C, et al. Frequent de novo mutations and exon deletions in the C1inhibitor gene of patients with angioedema. *J Allergy Clin Immunol* 2000 Dec;106(6):1147–54. [PMID: 11112899]
10. Cicardi M, Bork K, Caballero T, et al. Evidence-based recommendations for the therapeutic management of angioedema owing to hereditary C1 inhibitor deficiency: consensus report of an International Working Group. *Allergy* 2012 Feb;67(2):147-57. [PMID: 22126399]