

UC Davis
Dermatology Online Journal

Title

Ectopic intestinal mucosa implanted on the perianal skin of a patient with Crohn disease

Permalink

<https://escholarship.org/uc/item/6r956088>

Journal

Dermatology Online Journal, 24(3)

Authors

Valenzuela-Oñate, Cristian Alejandro
Magdaleno-Tapia, Jorge
Ferrer-Guillen, Blanca
et al.

Publication Date

2018

DOI

10.5070/D3243038624

Copyright Information

Copyright 2018 by the author(s). This work is made available under the terms of a Creative Commons Attribution-NonCommercial-NoDerivatives License, available at <https://creativecommons.org/licenses/by-nc-nd/4.0/>

Ectopic intestinal mucosa implanted on the perianal skin of a patient with Crohn disease

Cristian Alejandro Valenzuela-Oñate MD, Jorge Magdaleno-Tapia MD, Blanca Ferrer-Guillen MD, Pablo Hernández-Bel MD

Affiliations: Valencia University General Hospital Consortium, Valencia, Valencian Community, Spain

Corresponding Author: Cristian Alejandro Valenzuela Oñate, Mariano de Cavia #17 Door 13, Valencia, Spain, Postal Code: 46014, Email: cvalenzuela760@gmail.com

Abstract

Intestinal mucosa implanted in skin is an exceedingly rare occurrence. Implantations are thought to occur during the creation of ostomy sites or other surgical procedures in which suture goes through bowel mucosa and then skin. Current ostomy literature reports this as a very uncommon complication. We present a 54-year-old man diagnosed with Crohn disease with severe perianal involvement who was referred to our outpatient clinic because of two persistent perianal cutaneous ulcerations. He previously underwent several interventions to drain complex perianal fistulas and abscesses, the last of them involved placing seton stitches to ensure continuous draining during the healing process. Physical examination revealed two painful ulcerations with bleeding on contact. A skin biopsy was performed, revealing ectopic intestinal mucosa with crypts, villi, and goblet cells. Perianal ulcerations characteristic of Crohn disease might be difficult to differentiate from ectopic implant of bowel mucosa secondary to a surgical procedure in the perianal area. Therefore, we believe a high degree of suspicion and skin biopsy are key to the diagnosis.

Keywords: Crohn disease, ectopic intestinal mucosa

Introduction

Many tissues may occur ectopically on the skin, including neural tissue, salivary glands, thymus, mammary tissue, and gastrointestinal tissue [1]. The

ectopic presence of gastrointestinal tissue is an infrequent condition [2], but has been described at many locations, including tongue, mediastinum, scrotum, and spinal cord [1]. There is currently no consensus regarding the origin of this ectopic tissue. Some authors suggest that most cases are congenital in nature and believed to be a disorder in fetal development [3]. Other authors have suggested that it can be an acquired product of abnormal regeneration of mucosal cells in the setting of persistent inflammation [4]. However, skin-implanted intestinal mucosa is an exceedingly rare condition. Implantations are believed to occur during the creation of ostomy sites or other surgical procedures in which suture goes through bowel mucosa and then skin [3]. Current ostomy literature report this as a very uncommon complication.

Case Synopsis

A 54-year-old man diagnosed with Crohn disease with severe perianal involvement was referred by his gastroenterologist to our outpatient clinic because of two persistent perianal cutaneous ulcerations.

The patient was being treated with infliximab and azathioprine, but still suffered with 8 to 10 episodes of diarrhea per day. He previously underwent several interventions to drain complex perianal fistulas and abscesses, the last of them on November 2015 in which seton stitches were used to ensure continuous draining during the healing process. By the time he

was evaluated at our dermatology service on February 2017, the seton stitches were still in place and only presented mild perianal suppuration. Physical examination revealed two painful ulcerations with bleeding on contact (**Figure 1**). A skin biopsy of the lesions was performed.

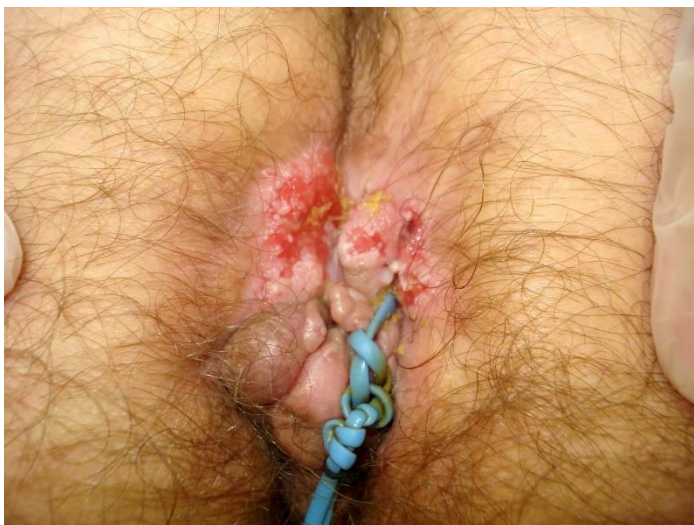

Figure 1. Perianal cutaneous lesions. Seton stitches in place.

Histopathological examination showed intestinal mucosa with crypts, villi and goblet cells (**Figure 2**). Diagnosis of implanted ectopic intestinal mucosa was made. Carcinoembryonic antigen was positive in the biopsy.

The patient was referred to the surgery department of our hospital for excision of the ectopic tissue.

Case Discussion

Our review of the literature identified 3 cases similar to ours' in which the origin of ectopic intestinal mucosa was theorized to be an acquired condition after iatrogenic implantation; all were related to the creation of an ostomy [1, 3, 5]. However, our patient

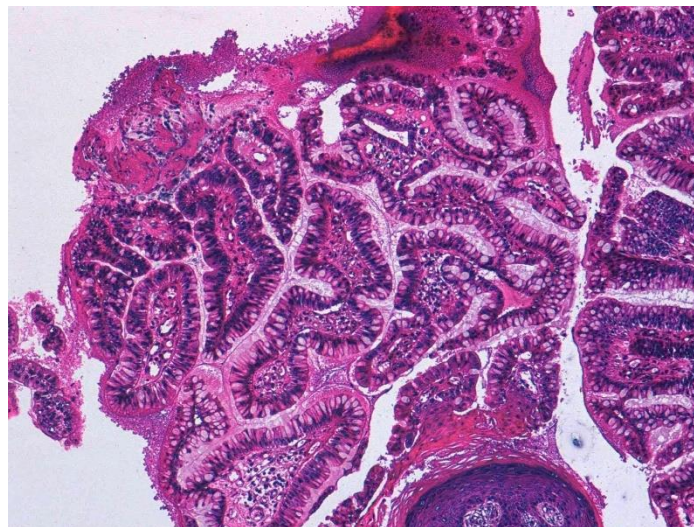


Figure 2. Skin biopsy: intestinal mucosa with crypts, villi and goblet cells. H&E, 20x.

is the first case related to a procedure different from the creation of an ostomy site and to our knowledge the only iatrogenic case of perianal location.

We believe that the lack of similar cases reported in the literature is because perianal ulcerations characteristic of Crohn disease might be difficult to differentiate from the ectopic implantation of bowel mucosa secondary to a surgical procedure in the perianal area.

Conclusion

We conclude that it is important to maintain a high degree of suspicion in patients with inflammatory intestinal disease with perianal involvement refractory to medical treatment. Ectopic intestinal mucosa could be present and a cutaneous biopsy is key for the diagnosis. With currently only a few cases reported it is unknown if any treatment different from the excision of the lesions is effective.

References

1. Esteve-Martinez A, Perez-Ferriols A, Alegre-de Miquel V. Implanted intestinal mucosa on the skin after an ileostomy. *Am J Dermatopathol.* 2014;36(11):930-1. [PMID: 24247581].
2. Pacilli M, Sebire NJ, Maritsi D, Kiely EM, Drake DP, Curry JI, Pierro A. Umbilical polyp in infants and children. *Eur J Pediatr Surg.* 2007;17(6):397-9. [PMID: 18072023].
3. Francis EP, Sandahl L, Reed MJ, Miller OF. Cutaneous presentation of ectopic small bowel mucosa. *J Am Acad Dermatol.* 2004;51(3):476-7. [PMID: 15337999].
4. Pacilli M, Sebire NJ, Maritsi D, Kiely EM, Drake DP, Curry JI, Pierro A. Umbilical polyp in infants and children. *Eur J Pediatr Surg.* 2007;17(6):397-9. [PMID: 18072023].
5. Ainsworth AP, Deleuran MS, Qvist N. [Abdominal skin affection caused by ectopic gut mucosa]. *Ugeskr Laeger.* 1999;161(22):3300-1. [PMID: 10485212].