

# UC Davis

## Dermatology Online Journal

### Title

A case of generalized red sweating

### Permalink

<https://escholarship.org/uc/item/73k8k695>

### Journal

Dermatology Online Journal, 21(3)

### Authors

Blalock, Travis W  
Crowson, A Neil  
Danford, Brandon

### Publication Date

2015

### DOI

10.5070/D3213022250

### Copyright Information

Copyright 2015 by the author(s). This work is made available under the terms of a Creative Commons Attribution-NonCommercial-NoDerivatives License, available at <https://creativecommons.org/licenses/by-nc-nd/4.0/>

Peer reviewed

## Case presentation

### A case of generalized red sweating

Brandon C. Danford BS<sup>1</sup>, A. Neil Crowson MD<sup>1,2,3</sup>, Travis W. Blalock MD<sup>1</sup>

Dermatology Online Journal 21 (3): 11

<sup>1</sup>University of Oklahoma College of Medicine, Department of Dermatology, Oklahoma City, Oklahoma

<sup>2</sup>Regional Medical Laboratory, Tulsa, Oklahoma

<sup>3</sup>University of Oklahoma College of Medicine, Department of Pathology, Oklahoma City, Oklahoma

## Correspondence:

Travis W. Blalock, MD  
Director of Dermatologic Surgery & Cutaneous Oncology  
Oklahoma University Health Sciences Center  
Department of Dermatology  
619 Northeast 13th St,  
Oklahoma City, OK 73104  
405-271-6110  
Travis-Blalock@ouhsc.edu

---

## Abstract

We report a case of a 70-year-old man with a 5-year history of red pigmented sweating on the axillae, groin, forearms, trunk, and peri-nuchal sites. No identifiable cause of the pigmented sweat was identified. Biopsy revealed lipofuscin pigment leading to the diagnosis of idiopathic chromhidrosis. This case represents an unusual presentation of chromhidrosis that was not limited to the apocrine sweat gland distribution and ultimately revealed no identifiable cause. After failing multiple treatment options, the patient elected for a trial of treatment with 20% aluminum chloride solution.

**Keywords: Chromhidrosis, Apocrine gland, Red sweat.**

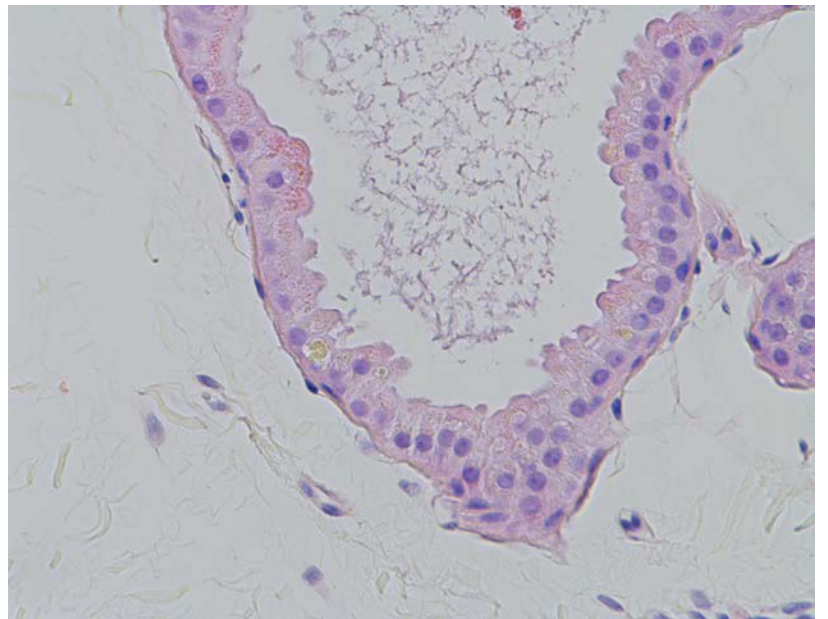
## Introduction

Chromhidrosis is a rare disorder that results in pigmentation of sweat and has been reported to affect both apocrine and eccrine sweat glands. It is an intrinsic process in which sweat is mixed with a pigmented substance prior to secretion, differentiating itself from pseudochromhidrosis in which sweat gains color after it mixes with pigment on the skin's surface. Most cases of apocrine chromhidrosis are attributed to oxidized lipofuscin within the gland, whereas cases of eccrine chromhidrosis are caused by ingested dyes or drugs. Before the diagnosis of chromhidrosis can be made, careful investigation is needed to rule out any causes of pseudochromhidrosis [1,2].

## Case synopsis

A 70-year-old white man presented with a 5-year history of red sweat from the axillae, groin, and peri-nuchal sites. He noted that he periodically had similar sweating from his forearms and trunk, though less frequently. Past medical history was significant for

arthritis, hypertension, high cholesterol, COPD, and gout. Current medications included losartan, rosuvastatin, metoprolol tartrate, allopurinol, and ranitidine. No changes to these medications prior to onset of the symptoms were noted. Upon physical examination, brick-red discoloration was observed in the axillae and on the collar of his shirt (Figure 1-2). Skin fungal culture, gram stain, and bacterial culture were all negative. Urine 5-hydroxyindoleacetic acid and urine organic acid levels were within normal limits. Attempted treatment with sulfamethoxazole/trimethoprim and topical clindamycin did not resolve symptoms. Histologic examination of a punch biopsy of the axilla revealed mildly dilated apocrine ducts with focal lipofuscin pigment (Figure 3).



**Figure 1.** Brick-red discoloration of patient's shirt sleeve. . **Figure 2.** Brick-red discoloration extending from neck to upper chest. **Figure 3.** Dilated apocrine glandular lumen with focal lipofuscin pigment (H&E, 20X).

## Discussion

Chromhidrosis is a rare disorder resulting in pigmentation of sweat in a variety of colors, but those most commonly reported are blue, black, green, brown, yellow, and red. Chromhidrosis has been known to affect both apocrine and eccrine sweat glands and understanding of this distribution may help in determining etiology and optimizing treatment. Apocrine sweat glands are concentrated in the axillae, groin, and areola; eccrine sweat glands are involved in thermoregulation and diffusely distributed over the entire body [1]. Cases of apocrine chromhidrosis have been reported in the literature, whereas true eccrine chromhidrosis cases are scarce and less documented. Although the presentation of apocrine and eccrine chromhidrosis can be similar, the pathophysiology of these two entities is quite different.

Apocrine chromhidrosis is an intrinsic process in which oxidized lipofuscin pigments are mixed with sweat inside the sweat gland and then expressed to the surface [1]. The reason for increased oxidation of lipofuscin granules in apocrine sweat glands in

patients with chromhidrosis is still unclear. This process is different from cases of true eccrine chromhidrosis. Eccrine chromhidrosis is the result of dyes or drugs that mix with sweat within the gland then are expressed to the surface [2]. Cases of purely eccrine chromhidrosis are rare and most cases are pseudochromhidrosis rather than true chromhidrosis.

Pseudochromhidrosis is an extrinsic process in which the sweat is initially colorless until it mixes with pigments, dyes, or chemicals on the skin's surface [2]. This differentiates chromhidrosis from pseudochromhidrosis. Common causes of pseudochromhidrosis are heavy metals, chemicals, clothing dye, and self-tanning products [2]. Many fungal and bacterial pigments have also been reported as the cause of pseudochromhidrosis [2]. Some physicians may attempt trial courses of systemic or topical antibiotics for this reason if the initial assessment does not reveal any obvious cause of chromhidrosis.

The initial assessment of a patient who presents with pigmented sweat should include a detailed history. Also, careful attention should be paid to any new medications started close to the onset of symptoms, which include herbal medications, vitamins, and other supplements. Fungal and bacteria cultures of the skin should be performed to eliminate the option of mere pseudochromhidrosis [2]. Urine studies may be useful and should include urine organic acids and 5-hydroxyindoleacetic acid to rule out alkaptonuria, which is a rare cause of chromhidrosis.

Although treatment for pseudochromhidrosis has been successful with systemic antibiotics, topical antibiotics, or cessation of the offending agent, few treatments have been successful in the treatment of chromhidrosis. Botulinum toxin type A and capsaicin have been named in the literature as treatment options, but both options have limitations [3, 4]. Botulinum toxin type A has been effective for focal chromhidrosis, such as in the axillae, although treatment of large areas can become costly. Capsaicin is an inexpensive treatment option, but treatment is only effective if the patient continues therapy. Capsaicin can result in intolerable pain, pruritus, soreness, itching, and other local side effect; cessation of treatment results in recurrence of symptoms.

This case of chromhidrosis has been determined to be idiopathic because any known organic causes of chromhidrosis have been eliminated. In our patient, fungal and bacterial cultures were both negative and alkaptonuria was ruled out with urine studies. The chromhidrosis could be the result of a medication the patient has been on although the patient has not started any new medication in over 5 years, which makes drug-induced chromhidrosis unlikely.

## Conclusion

In this case report we present an atypical presentation of an uncommon disease. This was a case of biopsy proven chromhidrosis with clinical symptoms that were not confined to the apocrine sweat gland distribution. Common causes of pseudochromhidrosis were excluded as being causative with skin cultures and trials of antibiotics failing to resolve the symptoms. Although benign, this condition can be a cause of embarrassment for patients. With poor treatment options available, it can be frustrating for provider and patient alike.

## References

1. Carman, Kursat Bora, Sultan D. Aydogdu, Ilham Sabuncu, Coskun Yazar, Ayten Yakut, and Bahar Öztelcan. "Infant with Chromhidrosis." *Pediatrics International* 53.2 (2011): 283-84. [PMID: 21501318]
2. Tato, Berta Pérez, Elena Zamora Martínez, Begoña Sánchez Albisua, Yosmar C Pérez González, Isabel Polimón Olabarrieta, and Silvia Marinero Escobedo. "Facial and Axillary Apocrine Chromhidrosis." *Dermatology Online Journal, UC Davis*, 2012. Web. 15 May 2014. [PMID: 22483524]
3. Marks J.G., Treatment of apocrine chromhidrosis with topical capsaicin. *J Am Acad Dermatol* (1989) 21 : pp 418-420. [PMID: 2474015]
4. Matarasso SL. Treatment of facial chromhidrosis with botulinum toxin type A. *J Am Acad Dermatol*. 2005;52:89-91. [PMID: 15627085]