

UC Davis

Dermatology Online Journal

Title

"Knife-cut" intertriginous ulcers related to herpes simplex virus in three patients

Permalink

<https://escholarship.org/uc/item/91n125fg>

Journal

Dermatology Online Journal, 28(4)

Authors

Millan, Sarah
Ali, Rowanne
Sanfilippo, Eric
et al.

Publication Date

2022

DOI

10.5070/D328458529

Copyright Information

Copyright 2022 by the author(s). This work is made available under the terms of a Creative Commons Attribution-NonCommercial-NoDerivatives License, available at <https://creativecommons.org/licenses/by-nc-nd/4.0/>

Peer reviewed

“Knife-cut” intertriginous ulcers related to herpes simplex virus in three patients

Sarah Millan¹ MD, Rowanne Ali¹ BS, Eric Sanfilippo¹ BS, Marc Siegel^{1,2} MD, Michael A Cardis³ MD, Karl M Saardi^{1,2} MD

Affiliations: ¹School of Medical and Health Sciences, George Washington University, Washington, District of Columbia, USA, ²Medical Faculty Associates, George Washington University, District of Columbia, USA, ³Department of Dermatology, MedStar Washington Hospital Center, Washington, District of Columbia, USA

Corresponding Author: Karl M Saardi MD, 2150 Pennsylvania Ave NW, 2S-103, Washington, DC 20037, Tel: 202-741-2600, Email: ksaardi@mfa.gwu.edu

Abstract

Linear intertriginous erosions and ulcerations related to herpes simplex virus (HSV) infection have been reported in patients with underlying immunosuppression. This rare presentation of HSV seems to occur predominantly in patients undergoing treatment of hematologic malignancies and rheumatologic conditions. Herein, we report three cases of linear “knife-cut” ulcerations in patients who were not undergoing active pharmacologic immunosuppressive therapy and lacked coexisting malignancy or autoimmune disease. Close examination of the skin folds for HSV infection is warranted to rule out disseminated infection as early intervention can be lifesaving.

Keywords: general dermatology; medical dermatology; inpatient dermatology, herpes simplex, infectious disease, viral disease

Introduction

Linear ulcerations related to herpes simplex virus (HSV) infection are believed to be a rare phenomenon. Historically, this morphology has been seen as a cutaneous manifestation of Crohn disease and designated as the “knife-cut” sign. There are, however, a few reported cases of this “knife-cut” ulceration due to HSV in patients with no personal or family history of Crohn disease. These cases presented patients with knife-cut ulcerations related to HSV in the setting of substantial, long-term

immunosuppression. We describe three patients seen as inpatient consultations with knife-cut ulcerations with HSV, all of whom had no personal or family history of Crohn disease. Furthermore, these patients shared similar medical histories and lacked long-standing autoimmune disease, immunosuppressive therapy, or active malignancy.

Case Synopsis

Case 1

A 61-year-old man with history of severe developmental delay, chronic kidney disease, peripheral vascular disease, and morbid obesity was admitted for altered mental status and hypothermia secondary to suspected sepsis. Despite broad spectrum antibiotic treatment, he deteriorated, requiring endotracheal intubation and admission to the intensive care unit. A dermatology consultation was requested and on examination, the patient had innumerable punched-out, clean-based ulcers on the buttocks, flanks, genitals, and legs. The ulcers coalesced to form linear lesions in the inguinal and abdominal folds, resembling cuts from the blade of a knife (**Figure 1A**). Disseminated HSV was suspected, and swabs of the intertriginous ulcers were positive for HSV2 by PCR. A punch biopsy was performed, which revealed superficial ulceration with multinucleation and ballooning degeneration, and an HSV immunohistochemical stain was positive (**Figure 1B**). Due to persistent altered mental status, a lumbar puncture was performed and PCR of the

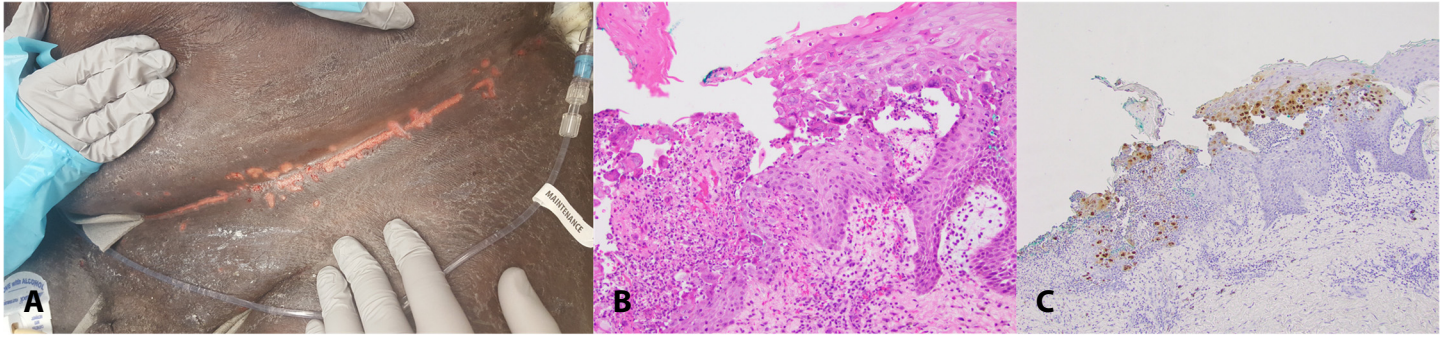


Figure 1. **A)** Abdominal intertriginous HSV2-positive linear erosions in a man with cardiovascular and renal disease presenting with disseminated HSV infection. **B)** corresponding histopathology revealing multinucleation and ballooning degeneration, H&E, 20 \times , and **C)** positive immunostaining for HSV, 10 \times .

cerebrospinal fluid was also positive for HSV2. Intravenous renally-dosed acyclovir was started, and the patient had gradual improvement in his mental status with healing of the cutaneous ulcers.

Case 2

A 72-year-old woman with a history of hypertension, end-stage renal disease (ESRD) requiring hemodialysis, grand-mal seizures, chronic cognitive dysfunction, and morbid obesity was transferred to our institution for mitral valve replacement because of infective endocarditis. The patient was a resident of a long-term acute care hospital as a result of previous strokes. Her preoperative course was notable for a drug-induced rash treated with 20 days of oral corticosteroids. Her postoperative course was then complicated by heparin-induced thrombocytopenia (HIT) with skin necrosis of the breasts. A dermatology consultation was requested for oral mucositis and skin ulcers in the inguinal and abdominal folds. Examination revealed mucositis of

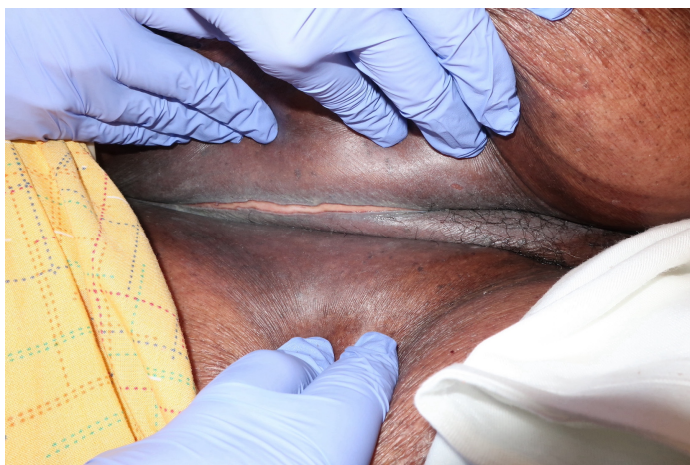

Figure 2. Intertriginous HSV1-positive linear, angulated ulceration in an abdominal fold of a female with renal failure.

the lower lip with scalloped borders, full-thickness ulceration over the ischial processes with eschar formation, small, punched-out ulcerations on the buttocks, and linear, angulated ulcers in the abdominal folds (**Figure 2**). Non-inflammatory retiform purpura with eschar formation related to HIT was also noted on the breasts. Swabs of the intertriginous ulcers were positive for HSV1 by PCR and treatment with intravenous acyclovir was started. Despite mitral valve replacement and clearance of blood cultures, the patient continued to deteriorate and ultimately died from septic shock, most likely related to numerous non-healing cutaneous wounds.

Case 3

A 74-year-old woman with a history of hypertension, type two diabetes mellitus, pulmonary embolisms, lower extremity deep vein thrombosis (DVT), breast cancer status post lumpectomy, and morbid obesity was admitted for delirium, left lower extremity swelling, and hypotension with tachycardia after weeks of poor oral intake. She was afebrile but was found to have a nidus for infection on her lower abdomen (**Figure 3**) and acute kidney injury caused by prerenal azotemia. Blood samples were sent for culture, and she was subsequently started on doxycycline and nystatin out of concern for intertrigo or cellulitis.

Intravenous hydration improved her symptoms and blood pressure and returned her mentation to baseline within 24 hours. Venous duplex ultrasound confirmed left leg DVTs, attributed to subtherapeutic anticoagulation secondary to medication nonadherence and anticoagulation therapy was

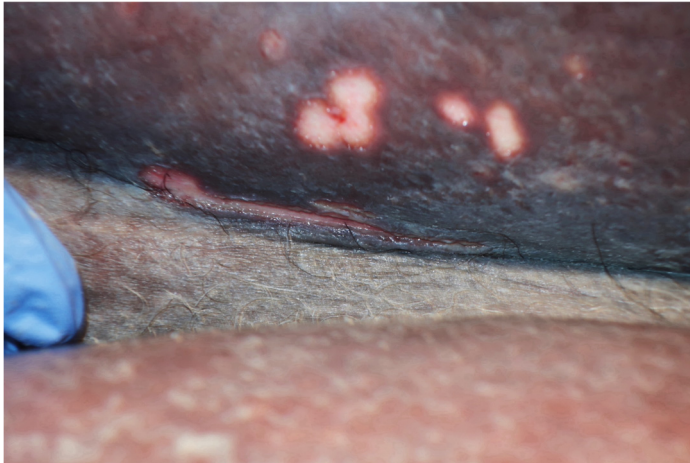


Figure 3. Abdominal, intertriginous linear ulceration with discrete and confluent erosions in a female with acute kidney injury, lower extremity deep vein thrombosis, and a remote history of breast cancer.

started. Computed tomography scans of the abdomen and head were unremarkable. Cultures of blood specimens returned negative for pathogens. A dermatology consultation was requested for persistence of the lower abdominal lesions despite treatment. During evaluation, the patient described the lesions as painful and reported their presence for over one month. She denied pain with urination and defecation. Physical examination was remarkable for a knife-like ulceration under the left pannus and numerous punched-out erosions and ulcers under the pannus on the lower abdomen, mons pubis, vulva, and inguinal folds. Polymerase chain reaction for HSV revealed HSV2 DNA only, confirming cutaneous HSV reactivation in the setting of acute illness. The patient was started on a twice-daily course of renally-dosed oral valacyclovir for 7 days and was instructed to continue the 5-day course of antibiotics to cover any secondary bacterial infection.

Case Discussion

Most cases of linear erosions related to HSV (termed the “knife-cut sign”) have been reported in the setting of opportunistic infection, malignancy, autoimmune disease, or long-term immunosuppressive and immunomodulatory drugs [1-3]. The three patients we present here all had some degree of altered immunocompetence given

the presence of chronic kidney disease or type two diabetes, but comparatively less so than the immunosuppressed states traditionally seen in patients with “knife-cut” HSV lesions. Additionally, our patients all had morbid obesity, atherosclerotic disease, renal dysfunction, and an acute illness characterized by altered mental status and shock. Other than a short course of systemic corticosteroids in case 2 and a remote history of breast cancer in Case 3, none of the patients were on long-term immunosuppressive therapy or had underlying malignancy. Although Case 2 had ESRD requiring hemodialysis, the only other reported case of linear HSV ulcers in a patient with ESRD on hemodialysis was in the setting of concomitant autoimmune disease contributing to a largely immunosuppressed state [2]. Testing by PCR in all cases and immunohistochemical staining in Case 1 confirmed the presence of HSV in these linear ulcers. The principal diagnosis considered in such cases with “knife-cut” linear erosions is cutaneous Crohn disease, which is the disease that prompted the term “knife-cut” [3]. Consulting dermatologists should be mindful of skin changes in intertriginous folds which may be a clue to severe systemic illness related to HSV infection.

Conclusion

We describe three patients with PCR-confirmed HSV infection presenting as linear ulcerations in intertriginous areas and skin folds. The presence of these findings, described as the “knife cut sign,” may suggest disseminated HSV. For this reason, consulting dermatologists should examine the skin folds in patients with severe, systemic infections of unknown etiology. The “knife-cut sign” may be difficult to distinguish from Crohn disease, but with a negative history of Crohn disease and a presentation that is atypical for Crohn disease, this finding provides an important diagnostic clue distinctive for HSV infection. Patients with immunosuppression related to hematologic malignancy, rheumatologic disease, or pharmacologic therapy are at greatest risk for this uncommon presentation, but linear HSV ulcerations

may also be seen in hospitalized, chronically ill patients.

Potential conflicts of interest

The authors declare no conflicts of interest.

References

1. LeBoeuf NR, Lieb J, Grossman ME. Linear erosive herpes simplex virus: the 'knife-cut sign' in a patient on high-dose corticosteroids. *Clin Exp Dermatol.* 2010;35:557-8. [PMID: 20236288].
2. Lieb JA, Brisman S, Herman S, MacGregor J, Grossman ME. Linear erosive herpes simplex virus infection in immunocompromised patients: the "knife-cut sign". *Clin Infect Dis.* 2008;47:1440-1. [PMID: 18937574].
3. Cohen PR. The "knife-cut sign" revisited: a distinctive presentation of linear erosive herpes simplex virus infection in immunocompromised patients. *J Clin Aesthet Dermatol.* 2015;8:38-42. [PMID: 26557219].